



Isolated Cerebral Fat Embolism After Trauma

Esengül Liman¹, Ufuk Emre¹, Hüsniye Aslan¹, Veysel Erden², Yeşim Karagöz³, Yunus Emre Akman⁴

Isolated cerebral fat embolism is characterized with a decline in the level of consciousness, seizures, and neurological deficits after long bone fractures. In this report, we present a case of isolated cerebral fat embolism after femur fracture.

Keywords: Long bone fracture, cerebral fat embolism, trauma

Introduction

Fat embolism syndrome (FES) is a clinical picture that often develops after trauma accompanied by long bone fractures and as a result of fat particles entering the circulation. It is characterized by respiratory insufficiency and neurological system and skin findings (1, 2). An isolated cerebral fat embolism is a more rarely seen picture not accompanied by other systemic findings and is characterized by only neurological findings. In this article, we present the case of an isolated cerebral fat embolism not accompanied by respiratory and skin findings in a patient who became unconsciousness 72 h after humerus and femur fractures and in whom a common cerebral fat embolism was found in the magnetic resonance image (MRI).

Case Report

A 23-year-old male was followed due to right humerus and femur shaft fractures after a traffic accident; when he was neurologically examined due to the sudden onset of impaired consciousness in the 72nd hour after trauma, he was unconscious, had no response to auditory stimuli, and showed a flexor response to painful stimuli. His pupils were isochoric, and his brain stem reflexes were taken. A pathological reflex was not detected. In the T2A and FLAIR sequences of the brain MRI of the patient with no feature in brain CT, a bilateral caudate nucleus was found in the subcortical white matter, common hyperintense areas were found with millimetric dimensions in the frontoparietal cortical and deep white matter, and diffusional restrictions were found in diffusion-weighted images (DWIs) (Figure 1). There were no respiratory complications or skin findings on performing a physical examination. During the neurological examination of the patient 5 days later, his eyes were spontaneously open, there was no word output, and there were movements in the extremities with painful stimuli. A pathological reflex was not detected. An improvement was observed in the patient's neurological examination findings in the first month of the follow-up with supportive care in the intensive care unit. Informed consent was received from the patient.

Discussion

Fat embolism syndrome is a rare clinical picture that progresses with respiratory, hematological, neurological, and skin findings (1-3). Although this picture, which is seen in 5% of patients with severe and multiple orthopedic trauma, occurs after trauma accompanied by long bone fractures, it can also be less frequently seen after severe burns, pancreatitis, liposuction, bone marrow transplantation, and vertebroplasty (3-5). According to the mechanical theory of Gauss, it has been reported in pathophysiology that it develops as a result of the damage in the fat tissue, ruptured veins within the damaged zone, and the passage of free fat particles through open-ended veins. According to the biochemical theory defined by Lehman, inflammatory cascade plasma mediators that develop as a result of the damage are reported to trigger the mobilization of fat particles from the reservoir (6). Diagnostic criteria have been developed by Gurd and Wilson for the diagnosis of a fat embolism. According to these criteria, respiratory symptoms and cerebral findings developing without petechiae in the skin

¹Clinic of Neurology, Istanbul Training and Research Hospital, Istanbul, Türkiye

²Clinic of Anesthesiology and Reanimation, Istanbul Training and Research Hospital, Istanbul, Türkiye

³Clinic of Radiology, Istanbul Training and Research Hospital, Istanbul, Türkiye

⁴Clinic of Orthopedics and Traumatology, Istanbul Training and Research Hospital, Istanbul, Türkiye

Address for Correspondence:
Esengül Liman
E-mail: esengulliman@hotmail.com

Received:
26.05.2015

Accepted:
16.02.2016

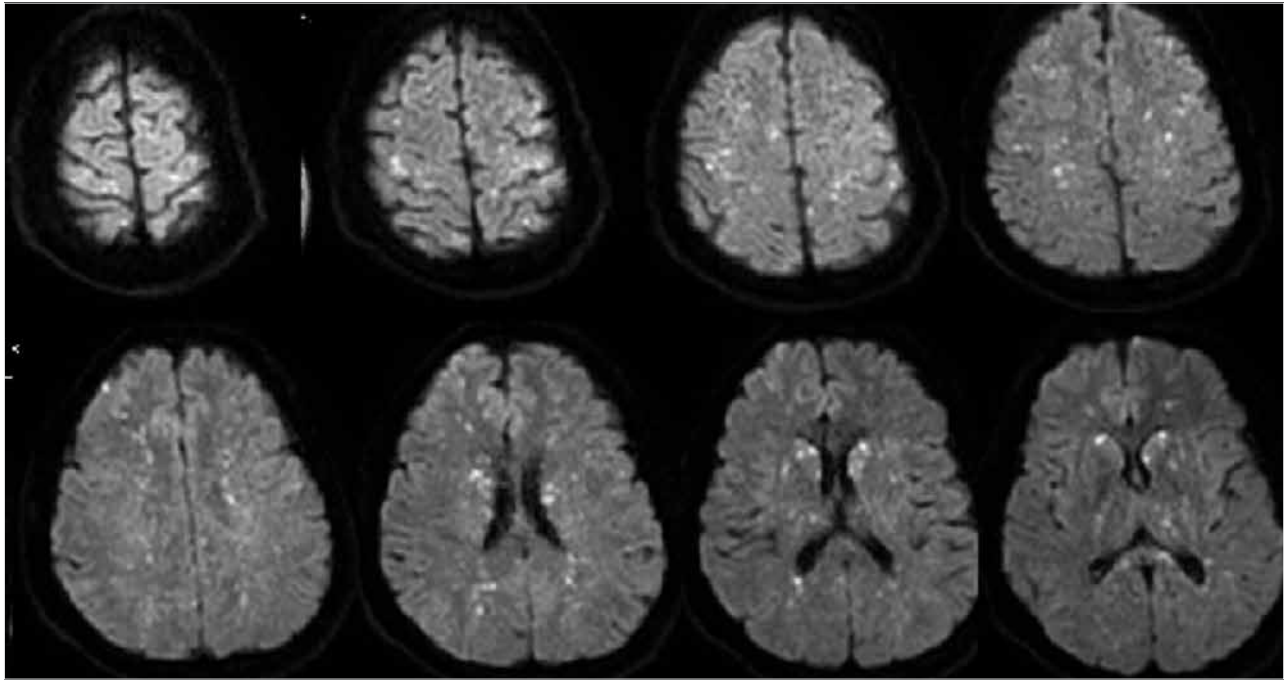


Figure 1. DWIs of the patient in the acute phase
DWI: diffusion-weighted images

and trauma in the head can be considered as major criteria and fever, tachycardia, retinal fat or petechiae, sudden decrease in hemoglobin levels and platelet counts, oliguria, and increased sedimentation rates can be considered as minor criteria. One major and four minor criteria or macroglobulinemia are sufficient for making a diagnosis (6). Schonfeld et al. (7) reported that the fat embolism score should be 5 or more in the first 3 days of hospitalization for the diagnosis of FES.

Fat embolism syndrome should be remembered in patients with petechiae, changes in consciousness, and respiratory failure during the first 3 days following severe trauma or orthopedic surgery (3). We had clinical findings approximately 3 days after trauma in our patient. Neurological signs and symptoms ranging from unconsciousness to epileptic seizures and focal neurological deficits can rarely be seen in clinics without other systemic findings (2). The most common is impaired consciousness. Almost all neurological deficits are temporary. In our clinic, except for unconsciousness, no findings compatible with the skin or the pulmonary embolism were detected in our patient.

Early-brain magnetic resonance imaging is important in the diagnosis. Brain magnetic resonance imaging is the most sensitive imaging method for a cerebral fat embolism, and multiple hyperintense nodules or point foci can be seen in the T2 sequence 4 h after the onset of a cerebral fat embolism. These point lesions, which are widespread and tend to merge in the subcortical and border areas in the white and gray matter, emerge as a result of cytotoxic and vasogenic edema. In DWIs, the appearance is pathognomonic in a starry sky pattern and reflects cytotoxic edema resulting from numerous microemboli. With the lesion load detected through diffusion-weighted imaging, Pfeffer showed that irreversible brain injury correlates with poor long-term clinical outcomes (6, 8). A diffusion restriction similar to global hypoxic-ischemic damage may be seen in the corpus callosum splenium and caudate nu-

cleus, but it is not associated with an adverse outcome in the FES. The SWI sequence contains diffuse hypointense lesions that reflect microhemorrhages and may be the only MRI sequence in which microhemorrhages can be seen (8).

Corticosteroids may be used in treatment to reduce brain edema, lung inflammation, and capillary endothelial destruction (3, 4). Intensive care follow-up was performed in our patient, and an improvement was observed in the clinical picture within weeks.

Conclusion

Fat embolism syndrome can rarely be seen with isolated neurological symptoms without respiratory insufficiency and skin findings, and the brain MRI may provide valued contributions in the early diagnosis of an isolated cerebral fat embolism.

Informed Consent: Informed consent was obtained from patients who participated in this study.

Peer-review: Externally peer-reviewed.

Author Contributions: Concept - E.L.; Design - E.L.; Supervision - U.E.; Funding - V.E.; Materials - Y.A.; Data Collection and/or Processing - Y.K.; Analysis and/or Interpretation - E.L.; Literature Review - H.A.; Writing - E.L.; Critical Review - U.E.

Conflict of Interest: No conflict of interest was declared by the authors.

Financial Disclosure: The authors declared that this study has received no financial support.

References

- Ozyurt Y, Erkal H, Ozay K, Arikan Z. Travmatik yağ embolisi sendromu: olgu sunumu. *Ulus Travma Acil Cerrahi Derg* 2006;12: 254-7.

2. Yıldız ÖK, Delice A, Öztoprak İ, Gürelık M, Yıldırım A, Bolayır E, Toptaş S. Cerebral Fat Embolism in the Absence of Systemic Manifestations of Fat Embolism Syndrome. *Türkiye Klinikleri J Neur* 2010; 5: 19-23.
3. Oymak FS, Güven M, Bilgin M, Gülmez İ, Demir R, Özemesi M. Yağ Embolisi Sendromu: Beş Olgunun Analizi. *Solunum Hastalıkları* 2000; 11: 308-13.
4. Erdoğan M, Bilgin M, Hasdıraz L, Büyükoğlan H, Öztürk M, Önal Ö, Kahraman A, Oğuzkaya F. Traumatic Fat Embolism Syndrome: Clinic Analysis of Cases. *Erciyes Med J* 2010; 32: 201-6.
5. Ahmadzai H, Campbell S, Archis C, Clark WA. Fat embolism syndrome following percutaneous vertebroplasty: a case report. *Spine J* 2014; 14: e1-5. [\[CrossRef\]](#)
6. Akoh CC, Schick C, Otero J, Karam M. Fat embolism syndrome after femur fracture fixation: a case report. *Iowa Orthop J* 2014; 34: 55-62.
7. Schonfeld SA, Ploysongsang Y, DiLisio R, Crissman JD, Miller E, Hamerschmidt DE, et al. Fat embolism prophylaxis with corticosteroids. A prospective study in high-risk patients. *Ann Intern Med* 1983; 99: 438-43. [\[CrossRef\]](#)
8. Mittal MK, Burrus TM, Campeau NG, Eckel LJ, Rabinstein AA, Wijdicks EF. Pearls & oysters: good recovery following cerebral fat embolization with paroxysmal hyperactivity syndrome. *Neurology* 2013; 81: e107-9. [\[CrossRef\]](#)