



## Isolated Mirror Movement Disorder: A Case Report

### İzole Ayna Hareketi Bozukluğu: Olgu Sunumu

Dilcan Kotan<sup>1</sup>, Belma Doğan Güngen<sup>2</sup>

Mirror movement is a rare condition and refers to involuntary movements that occur in homologous contralateral muscles during their voluntary movement. Mirror movements are present during normal development, decrease with maturation, and rarely persist beyond the first decade. The exact pathophysiology of this syndrome is still unclear. They may persist into adult life as the result of early cerebral damage due to stroke or congenital malformations (as in Klippel-Feil syndrome) or on a genetic basis transmitted as an autosomal dominant condition. Here, we have presented a rare case of observed isolated mirror movement in a male.

**Keywords:** Mirror movement, involuntary movement, homolog muscle

Ayna hareketi nadir bir durumdur ve kasların istemli hareketi sırasında karşı taraftaki homolog kasların istemsiz olarak benzer hareket ortaya çıkmasıdır. Ayna hareketi büyüme döneminde varolabilir, zamanla azalır ve çok nadiren onlu yaşlardan sonra devam eder. Bu sendromun fizyopatolojisi tam olarak bilinmemektedir. Erişkin dönemde, inmede olduğu gibi erken beyin hasarına, Klippel-Feil de olduğu gibi kojenital malformasyonlara veya otozomal dominant geçişli genetik nedene bağlı olarak kalıcı olabilir. Burada, çok nadir görülen izole ayna hareketi bozukluğu olan bir erkek olgu sunulmuştur.

**Anahtar Kelimeler:** Ayna hareketi, istemsiz hareket, homolog kas

Letter to Editor,

Dear Sir,

We observed a male patient with isolated mirror movement disorder 2 weeks ago. Here, we would like comment about a rare observed case.

Mirror movement is a rare condition and refers to involuntary movements that occur in homologous contralateral muscles during their voluntary movement. The exact pathophysiology of this syndrome is still unclear. Mirror movements are often observed in the upper extremities and rarely in the lower extremities (1, 2). Mirror movements are characterized for a set of hand muscles during a simple contraction task. It is frequently seen in the distal upper extremity; it is considered normal in early childhood, and then it disappears. Cerebral disinhibition or abnormal motor pathways are held to be responsible for the formation of these involuntary movements. Under normal conditions, as a result of a planned movement, the emergence of identical involuntary movements on the opposite side of the body is inhibited by the corpus callosum. In cases where the fibers in the corpus callosum fail to provide the necessary inhibition, mirror movement occurs on the opposite side of the voluntary movement (2, 3). It is seen frequently in childhood and is supposed to be physiological, but it is defined as a disorder in adulthood. Mirror movements are present during normal development, decrease with maturation, and rarely persist beyond the first decade.

Mirror movements may occur in various congenital or acquired disorders, such as Kallmann's syndrome, stroke, and hemiparkinsonism. They may persist into adult life as the result of early cerebral damage due to stroke or congenital malformations (as in Klippel-Feil syndrome) or on a genetic basis, transmitted as an autosomal dominant condition. It may be sporadic or familial. Treatment of the congenital disorder is not necessary (3, 4).

An 18-year-old male patient was admitted to the hospital with the complaint that he could not prevent the other hand from doing similar movements while using one of his hands. It was learned from his anamnesis that he realized this situation since elementary school, it became more pronounced over the years, and he had difficulties tying his shoelaces, carrying weight, and placing items. The medical history and familial history were unremarkable. The physical examination was normal. The only finding in the neurological examination was marked mirror movement disorder during paper cutting, punching, and shoelace tying in the distal upper extremity. The routine examination and EEG were normal. The cranial MRI was unremarkable.

<sup>1</sup>Department of Neurology, Sakarya University, Medicine of Faculty, Sakarya, Türkiye

<sup>2</sup>Department of Neurology, Sakarya University Research and Training Hospital, Sakarya, Türkiye

**Address for Correspondence**

**Yazışma Adresi:**

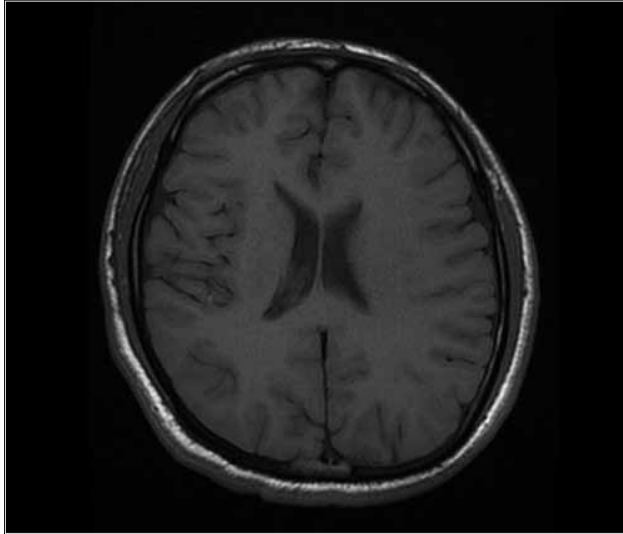
Dilcan Kotan, Department of Neurology, Sakarya University, Medicine of Faculty, Sakarya, Türkiye  
Phone.: +90 533 387 08 10  
E-mail: dkotan@sakarya.edu.tr

Received/Geliş Tarihi:  
15.07.2014

Accepted/Kabul Tarihi:  
02.10.2014

© Copyright 2014 by Available online at  
www.istanbulmedicaljournal.org

© Telif Hakkı 2014 Makale metnine  
www.istanbultipdergisi.org web sayfasından  
ulaşılabilir.



**Figure 1.** Cranial MRI was unremarkable except for slight asymmetry in the ventricle

except for slight asymmetry in the ventricle (Figure 1). The cervical MRI was normal. All of these findings were diagnosed as isolated mirror movements.

Mirror movements are involuntary movements during the voluntary movements of the contralateral homologous body parts. Our case had marked mirror movement disorder in the distal upper extremity. The pathophysiological mechanisms of mirror movements vary according to the pathological condition. Although the exact pathophysiology of persistent mirror movements is unknown, various hypotheses are propounded, such as ipsilateral corticospinal tract and abnormal inhibitory transcallosal connections (3, 5).

In recent years, functional magnetic imaging and stimulation and neurophysiological studies (for example, bilateral motor evoked potential, cortical silent period) of mirror movements associated with bilateral cortical activity have been increasing. Therefore, transcallosal mirror movement decreased or increased inhibition may result transcallosal facilitation. On the other hand, the influenced intracortical inhibition may be reduced (4).

They are considered normal in early childhood. This tends to disappear before 10 years of age, coincident with myelination of the corpus callosum; and symptomatic or pathological mirror movements, which is associated with several neurologic conditions such as congenital hemiparesis, agenesis of corpus callosum, Kallmann's syndrome, phenylketonuria, diabetes insipidus, cerebral damage (tumor, stroke, trauma), schizophrenia, and Parkinson disease (3, 5, 6). Recently, a lot of mutations have been identified in mirror movement, but they are genetically heterogeneous. Our case noticed the disorder in early childhood and was normal in the

neurological and psychiatric examination and brain and cervical MRI. We emphasize that isolated mirror movements are not always symptomatic or genetic.

Best Regards,

**Informed Consent:** Written informed consent was obtained from patient who participated in this study.

**Peer-review:** Externally peer-reviewed.

**Author Contributions:** Concept - D.K.; Design - D.K.; Supervision - D.K., B.D.G.; Funding - D.K.; Materials B.D.G.; Data Collection and/or Processing - D.K., BDG; Analysis and/or Interpretation - DK Literature Review - D.K.; Writing - D.K.; Critical Review - D.K., B.D.G.

**Conflict of Interest:** No conflict of interest was declared by the authors.

**Financial Disclosure:** The authors declared that this study has received no financial support.

**Hasta Onamı:** Yazılı hasta onamı bu çalışmaya katılan hastadan alınmıştır.

**Hakem değerlendirmesi:** Dış bağımsız.

**Yazar Katkıları:** Fikir - D.K.; Tasarım - D.K.; Denetleme - D.K., B.D.G.; Kaynaklar - D.K.; Malzemeler - B.D.G.; Veri toplanması ve/veya işlemesi - D.K., BDG; Analiz ve/veya yorum - D.K.; Literatür taraması - D.K.; Yazıyı yazan - D.K.; Eleştirel inceleme - D.K., B.D.G.

**Çıkar Çatışması:** Yazarlar çıkar çatışması bildirmemişlerdir.

**Finansal Destek:** Yazarlar bu çalışma için finansal destek almadıklarını beyan etmişlerdir.

## References

1. Andrew G Herzog, Herbert F Durwen. Mirror Movement Anthony B Joseph, Robers R Young. Movement disorders in Neurology and neuropsychiatry, Second ed. Blackwell Science; Vol.-II, 656-63.
2. Cattaneo L, Rizzolatti G. The mirror neuron system. Arch Neurol 2009; 66: 557-60. [CrossRef]
3. Lepage J, Théoret H. The mirror neuron system: grasping others' actions from birth? Developmental Science 2007; 5: 513-23. [CrossRef]
4. Cincotta M, Borgheresi A, Balestrieri F, Giovannelli F, Ragazzoni A, Vanni P, et al. Mechanisms underlying mirror movements in Parkinson's disease: A transcranial magnetic stimulation study. Mov Disord 2006; 21: 1019-25. [CrossRef]
5. Casile A, Caggiano V, Ferrari PF. The mirror neuron system: A fresh view. Neuroscientist 2011; 17: 524-38. [CrossRef]
6. Molenberghs P, Brander C, Mattingley JB, Cunnington R. The role of the superior temporal sulcus and the mirror neuron system in imitation. Hum Brain Mapp 2010; 9: 1316-26. [CrossRef]