

Retroperitoneal Paraganglioma: Case Presentation

Retroperitoneal Paragangliom: Olgu Sunumu

Didem KARAÇETİN,¹ Ahmet HALEFOĞLU,² Fevziye KABUKÇUOĞLU,³ Zeynep TATAR⁴

SUMMARY

Paragangliomas are rare neoplasms arising from undifferentiated cells of the primitive neural crest. We report a case of a 58-year-old female patient who presented with a large tissular retroperitoneal tumor situated above the left kidney. Serum epinephrine and norepinephrine levels were normal, and vanillylmandelic acid (VMA) was 13.9 mg/24 hours. Complete resection of the tumor was performed without intra-operative incident. The histopathological examination and the immunohistochemical analyses concluded the diagnosis of a retroperitoneal paraganglioma.

Key words: Retroperitoneal paraganglioma; vanillylmandelic acid.

ÖZET

Paragangliomlar ender, farklılaşmamış hücrelerden kaynaklanan primitif nöral krest tümörleridir. Bu olgu sunumunda, sol böbrek üstünde büyük dokulu retroperitoneal tümör bulunan 58 yaşındaki kadın hasta sunuldu. Hastanın serum epinefrin ve norepinefrin düzeyleri normal idi, vanililmandelik asit değeri 13.9 mg/24 saat olarak bulundu. Ameliyatla tümörün komple rezeksiyonu sorunsuz olarak yapıldı. Histopatolojik ve immünohistokimyasal analizler sonucunda retroperitoneal paragangliom tanısı konuldu.

Anahtar sözcükler: Retroperitoneal paragangliom; vanililmandelik asit.

INTRODUCTION

Retroperitoneal paragangliomas, develop in the paraganglion chromaffin cells of the sympathetic nervous system.^[1,2] Clinical presentation, diagnosis, and treatment are similar to adrenal tumors. Patients should be closely monitored with serum and urine catecholamine determination. Paragangliomas usually are considered benign. Traditionally the mainstay treatment has been surgical removal, but repeated cases treated by radiotherapy.

CASE REPORT

A 58-year-old female patient was referred to hospital because of severe hypertension. She had constipation and abdominal pain. She had also recurrent nose bleeds.

In her abdomen computed tomography (CT) scans showed, 5-6 cm mass in retroperitoneal area which line to left renal pelvis and push renal vein (Fig. 1a, b).

Notable laboratory findings included normal urinary and serum norepinephrine levels, normal urinary and serum epinephrine levels, an elevated urinary vanillylmandelic acid (VMA) level of 13.9 mg/24 h (normal, 0.6-8 mg/24 h),.

The patient underwent surgical exploration, and tumor resection was performed (Fig. 2).

In microscopically examination; the tumor cells which have eosinophilic and faintly granular cytoplasm with indistinct borders within individual cell clusters tend to be haphazardly distributed without

¹Department of Radiation Oncology, Şişli Etfal Training and Research Hospital, İstanbul

²Department of Radiology, Şişli Etfal Training and Research Hospital, İstanbul

³Department of Pathology, Şişli Etfal Training and Research Hospital, İstanbul

⁴Department of Pathology, Haseki Training and Research Hospital, İstanbul

Correspondence (İletişim): Didem Karaçetin, M.D. e-mail (e-posta): didemkaracetin@gmail.com

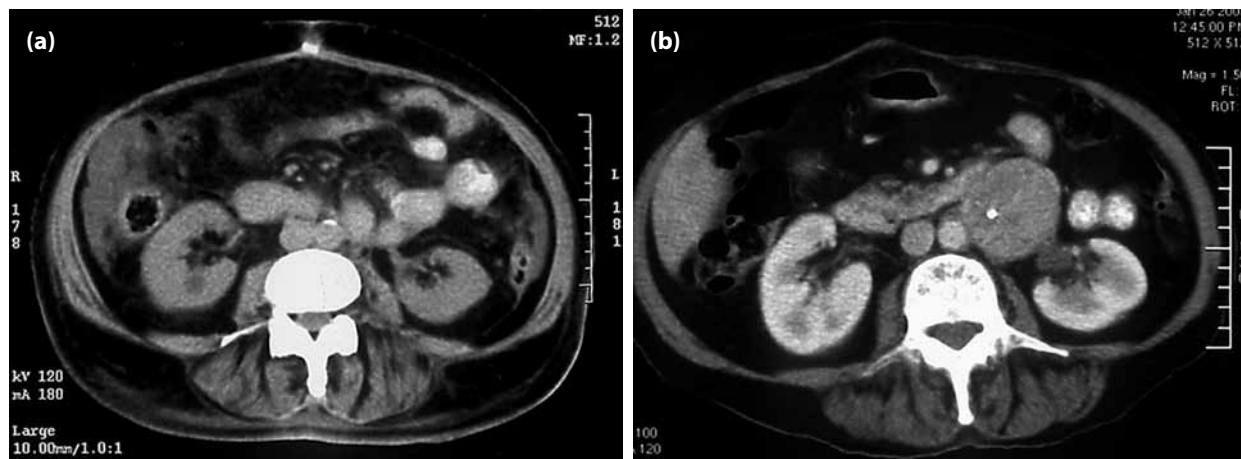


Fig. 1. (a, b) Abdomen CT imaging before surgery.

polarization along the fibrovascular septa. Well defined nests are separated by highly vascularized fibrous septa. There is minimal cellular atypia in this tumour as with many other endocrine tumors but there is no mitotically active cell.

In immunohistochemical examination showed strong and widely positivity with synaptophysin and vimentin. In other hand, there is no desmin and pan-cytokeratin reactivity in tumor cells. Diagnose of the paraganglioma is supported by this reactivity pattern (Fig. 3). In paraganglioma, tumor cells are almost

negative for cytokeratin and this is important in differential diagnosis with neuroendocrine carcinomas and pheochromocytoma.

After operation she followed up in Radiation Oncology Clinic. Physical examination was normal, CT scan of abdomen after operation was normal. Urine nor-metanephrine was 1.0 mg/24 hrs (normal: 0.0-1.2 mg/24 hrs), VMA: 5.4 mg/24 hrs. 24 months later she had severe hypertension attack, and when she arrived emergency clinic, she died because of myocardial infarction.

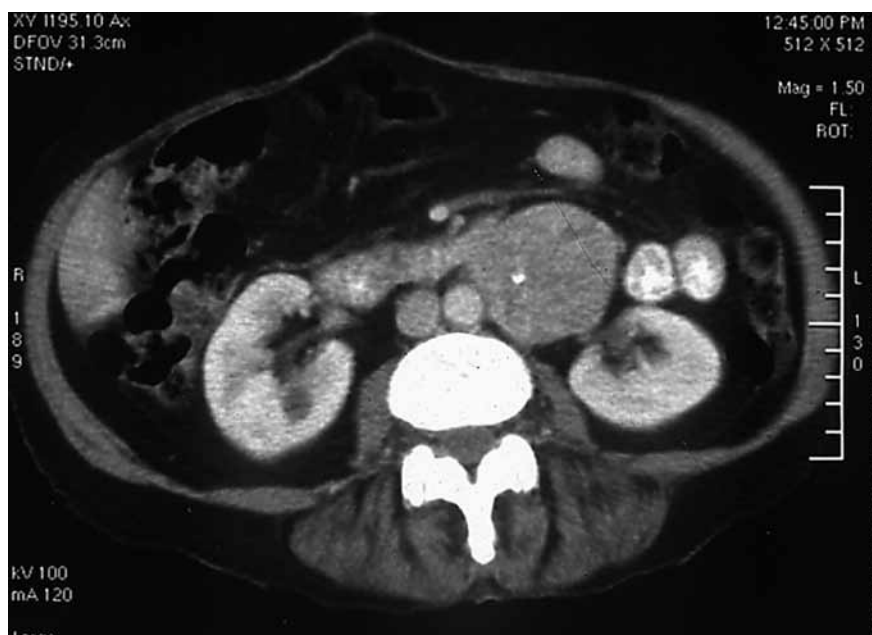

Fig. 2. Abdomen CT imaging after surgery.

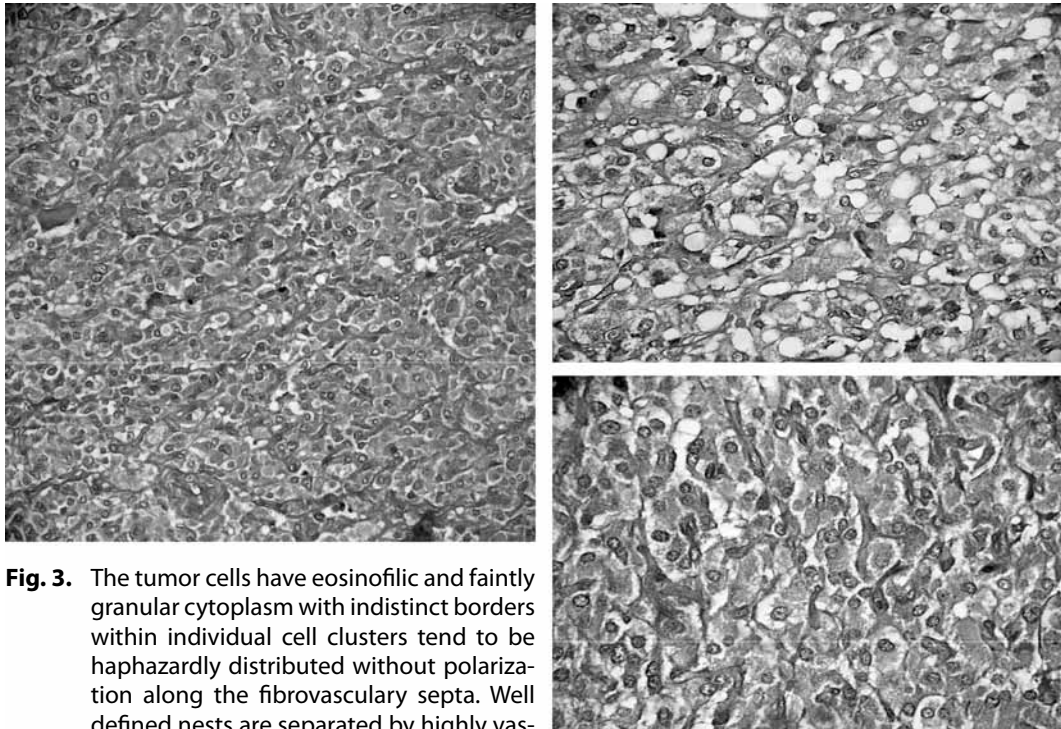


Fig. 3. The tumor cells have eosinophilic and faintly granular cytoplasm with indistinct borders within individual cell clusters tend to be haphazardly distributed without polarization along the fibrovascular septa. Well defined nests are separated by highly vascularized fibrous septa. There is minimal cellular atypia in this tumor as with many other endocrine tumors but there is no mitotically active cell.

DISCUSSION

Pheochromocytomas are rare primary neoplasms of the adrenal medulla that may produce catecholamines. Subsets of this tumor family that arise from tissue of the extraadrenal sympathetic nervous system are referred to as paragangliomas. Paragangliomas constitute only about 10% of pheochromocytomas and are therefore even rarer.^[3] Pheochromocytomas occur mainly in adults and are usually benign. The signs and symptoms can be related to excess catecholamine secretion and include paroxysmal hypertension accompanied by anxiety, sweating, a throbbing headache, and either facial pallor or flushing during the attack. A classic triad of symptoms that includes headache, sweating, and palpitations has been described in functional tumors. Rarely, if a paroxysm is sufficiently severe, a hypertensive crisis or myocardial infarction may occur, resulting in death.

In patients who present with symptoms suggestive of excess catecholamine production, laboratory tests can help detect active tumor secretion of epinephrine and norepinephrine by measuring catecholamines

and related metabolites in the plasma and urine. In this case, the major metabolic product of catecholamines, urinary VMA, was two times the normal level, a finding that is diagnostic for catecholamine-secreting tumors.^[1]

Nevertheless, 10-15% of such tumors are non-functioning, and in another 10% a hormone activity is not manifest clinically.

Ultrasonography serves as an excellent non-invasive first-line investigative diagnostic modality to pick up silent as well as functioning ectopic lesions. Doppler ultrasound demonstrates the highly vascular nature of these tumors.^[4]

In patients with known elevated catecholamines and normal appearing adrenal glands, the entire sympathetic chain must be evaluated with CT, for the presence of an extraadrenal paraganglioma. Although 90% of paragangliomas are contained within the adrenal gland as pheochromocytomas, the remaining 10% are located elsewhere along the sympathetic chain, including the skull base and neck (5% of cas-

es), thorax (10%), aorta (75%), and bladder (10%).^[5] When a paraganglioma is suspected, CT may help identify the responsible tumor as a soft-tissue mass (usually 3 cm) along the retroperitoneal path of the sympathetic nervous system. Magnetic resonance imaging (MRI) may be used to evaluate an adrenal or extraadrenal mass suspected to be a pheochromocytoma or paraganglioma.^[6]

I 131-labelled metaiodobenzylguanidine (MIBG) scintiscan is highly effective for location diagnosis, especially since it has a sensitivity of almost 100% in the diagnosis of extraadrenal pheochromocytoma.^[6]

Paragangliomas are tumors that arise from paraganglionic tissue and are further classified on the basis of anatomic origin. Paragangliomas of the adrenal medulla are known as pheochromocytomas. The majority of paragangliomas of the head and neck are nonfunctioning tumors of the parasympathetic system that are often brought to clinical attention by symptoms of mass effect rather than excess catecholamine. Paragangliomas that arise from the jugulotympanic body are known as chemodectomas because of the specialized cells at this location, which are sensitive to changes in blood gas levels. Paragangliomas of the carotid body are simply called carotid body tumors. Tumors below the neck are more frequently functional and associated with the sympathetic system.^[7]

There are several important clinical differences between adrenal pheochromocytomas and extraadrenal paragangliomas, particularly tumors that arise from the paraaortic sympathetic chain. First, sporadic adrenal pheochromocytomas will often affect patients in the 5th to 7th decades of life, with a slight female predilection. Extraadrenal paragangliomas will affect patients in the 2nd or 3rd decade of life, with genetic tumors having a male predilection. Second, familial forms are far more likely to be bilateral than are sporadic tumors. Finally, extraadrenal tumors are more likely to be multifocal than are adrenal lesions.

At gross examination, paragangliomas range from 1 to 6 cm in diameter, with malignant tumors tending to be slightly larger.^[8] They are firm, encapsulat-

ed masses that adhere to adjacent structures. On cut section, paragangliomas are tan-red, with or without areas of necrosis. Microscopic analysis demonstrates neuroendocrine cells arranged in clusters called Zellballen and interspersed with fibrovascular stroma. It is this vascular component that produces intense contrast enhancement at CT or MRI imaging. Functional tumors contain neurosecretory granules that give the tumor a granular appearance with silver stain. When catecholamines are oxidized by potassium dichromate solution, a dark brown staining results. This "chromaffin reaction" is used to distinguish tumors of sympathetic origin from parasympathetic neural tumors. Specific antibodies for neuroendocrine markers such as synaptophysin and chromogranin, as well as S-100 protein, may also be used to confirm the diagnosis.^[9]

Traditionally, the mainstay of treatment has been surgical removal,^[10] but repeated cases treated by radiation therapy for local control of these tumors.^[11] The authors recommended doses in the 4000 to 4500 cGy range delivered over 4-5 weeks.^[11] Essentially, chemotherapy has no defined role for treatment of paragangliomas, but only is used metastatic disease.^[12] Metastatic lesions have a poor prognosis, with a 5-year survival rate of 36% according to one study.^[13]

REFERENCES

1. Rekik W, Nouria Y, Binous MY, et al. Retroperitoneal paraganglioma: case report. *Tunis Med* 2004;82:1044-7.
2. Landsberg L, Young JB. Catecholamines and the adrenal medulla. In: Wilson JD, Foster DW, editors. *Williams Textbook of Endocrinology*. Philadelphia: W.B. Saunders Company; 1992. p. 621-705.
3. Thrasher JB, Rajan RR, Perez LM, et al. Pheochromocytoma of urinary bladder: contemporary methods of diagnosis and treatment options. *Urology* 1993;41:435-9.
4. Cronan JJ, Do HM, Monchik JM, et al. Bladder pheochromocytoma. Color Doppler sonographic correlation. *J Ultrasound Med* 1992;11:493-5.
5. Whalen RK, Althausen AF, Daniels GH. Extra-adrenal pheochromocytoma. *J Urol* 1992;147:1-10.
6. Heyman J, Cheung Y, Ghali V, et al. Bladder pheochromocytoma: evaluation with magnetic resonance imaging. *J Urol* 1989;141:1424-6.
7. Atiyeh BA, Barakat AJ, Abumrad NN. Extra-adrenal pheochromocytoma. *J Nephrol* 1997;10:25-9.

8. Pui MH, Liu MJ, Guo Y, et al. Computed tomography of retroperitoneal paragangliomas. *Australas Radiol* 1999;43:303-6.
9. Lack EE, Cubilla AL, Woodruff JM, et al. Extra-adrenal paragangliomas of the retroperitoneum: A clinicopathologic study of 12 tumors. *Am J Surg Pathol* 1980;4:109-20.
10. Bryant RL, Stevenson DR, Hunton DW, et al. Primary malignant retroperitoneal tumors. Current management. *Am J Surg* 1982;144:646-9.
11. Mikhail RA, Moore JB, Reed DN Jr, et al. Malignant retroperitoneal paragangliomas. *J Surg Oncol* 1986;32:32-6.
12. Mikhail RA, Moore JB, Reed DN Jr, et al. Malignant retroperitoneal paragangliomas. *J Surg Oncol* 1986;32:32-6.
13. Sclafani LM, Woodruff JM, Brennan MF. Extraadrenal retroperitoneal paragangliomas: natural history and response to treatment. *Surgery* 1990;108:1124-9; 1129-30.