

# A Ruptured Hydatid Cyst Case Applied to Emergency Unit with Urticaria and Syncope: A Case Report

## Ürtiker ve Senkopla Acil Servise Başvuran Periton İçine Rüptüre Kist Hidatik Vakası: Olgu Sunumu

Kenan BÜYÜKAŞIK,<sup>1</sup> Ahmet Burak TOROS,<sup>2</sup> Hakan TANIN,<sup>1</sup> Acar AREN<sup>1</sup>

### SUMMARY

Hydatid cyst is a parasitic infection caused by *Echinococcus granulosus* and *Echinococcus alveolaris*. This infection is characterized by cyst formations and can involve all organs in the body including liver and lung frequently. Hepatic hydatid cyst is generally asymptomatic. Main problem is the frequency and severity of complications. If the cyst is ruptured as a result of external trauma or spontaneously or during a surgical intervention, outcomes can range between a simple urticarial rash to anaphylactic shock or even death. In some rare conditions, the only sign of the rupture can be urticarial skin rashes and/or syncope. Here we present a 56-year-old female Turkish patient with hydatid cyst rupture in liver, who applied with urticaria and syncope as the result of spontaneous rupture and had a resistant hypotension, in accompany with the literature. We would like to emphasize that hydatid cyst rupture should be recurred to the mind in differential diagnosis of patients, who apply with allergic reactions and syncope.

**Key words:** Rupture of hydatid cyst; syncope; urticaria.

### ÖZET

Kist hidatik, *Echinococcus granulosus* ve *Echinococcus alveolaris* tarafından oluşturulan paraziter bir enfeksiyondür. Bu enfeksiyon kist oluşumu ile karakterize olup, en sık karaciğer ve akciğer tutulumu olmak üzere vücutta tüm organları tutabilir. Hepatik kist hidatik genellikle semptom-suzdur. Asıl sorun komplikasyonların sıklığı ve şiddetidir. Harici travma, spontan ya da cerrahi müdahale sırasında kistin rüptüre olması, basit bir ürtikeryal döküntüden ana-filaktik şok ve hatta ölüme kadar gidebilen sonuçlar orta-ya çıkarabilmektedir. Nadir bazı durumlarda rüptürün tek bulgusu ürtiker tarzı cilt döküntüleri ve/veya senkop ola-bilir. Bu olgu sunumunda, senkopla acil servise başvuran ve ürtiker tarzında cilt döküntüleri gelişen, kist hidatik rüptürü tanısı alan 56 yaşında bir Türk kadın hasta sunuldu. Allerjik reaksiyon ve senkopla başvuran hastalarda ayırıcı tanıda kist hidatik rüptürünün de akla gelmesi gerektiğini vurgulamak istedik.

**Anahtar sözcükler:** Hidatik kist rüptürü; senkop; ürtiker.

### INTRODUCTION

*Echinococcosis* or hydatid disease is formed by echinococcus larva. *Echinococcus granulosus* (EG) causes cystic echinococcosis and is widely encountered all over the world. EG requires two mammalian types to complete its life cycle. While dogs are actual hosts; sheep, cattle and humans are intermediate

hosts. Adult parasite is located in the small intestines of main hosts and leaves many eggs. These eggs are excreted by feces and are received through digestive system by the intermediate hosts, and are located in liver and lungs via portal circulation. Parasites continue to grow there and form cysts filled up with liquid. Humans are infected by contacting the infected dogs

Submitted (Geliş tarihi): 23.11.2011 Accepted (Kabul tarihi): 19.09.2012

<sup>1</sup>Department of General Surgery, Istanbul Education and Research Hospital, Istanbul

<sup>2</sup>Department of Internal Diseases, Istanbul Education and Research Hospital, Istanbul

Correspondence (İletişim): Dr. Ahmet Burak Toros. e-mail (e-posta): aburaktoros@yahoo.com

and eating the contaminated foods. Although hydatid cysts can be formed nearly all over the body, they are most frequently encountered in liver and lungs.<sup>[1-3]</sup>

Anaphylactic reactions can develop by mixing the antigenic content of the cyst into systemic circulation as a result of cyst rupture.<sup>[4,5]</sup>

Here we present a case of hydatid cyst rupture in liver, who applied with urticaria and syncope as the result of spontaneous rupture and had a resistant hypotension, in accompany with the literature.

### CASE REPORT

A 56-year-old female Turkish patient applied to the emergency unit with complaints of nausea, syncope, encopresis and enuresis. She was conscious, cooperated and oriented in the physical examination with BP (blood pressure) = 90/50 mmHg, pulse rate = 78/min, temperature= 36.5°C, and O<sub>2</sub> saturation was 94%. The abdominal examination was within normal limits without palpable liver and spleen. There were urticarial skin rashes in the patient's face.

In the laboratory examinations, there was eosinophilia (11.2%). There was no abnormal biochemical parameter other than increased LDH (350 U/L).

In abdominal ultrasonography (USG), there were 4-5 hydatid cyst lesions with the largest one of 110 X 71 mm size in the right lobe of liver, and widespread free liquid was observed between intestinal loops at the perihepatic-perisplenic and pelvic areas. An abdominal computerized tomography (CT) was also obtained (Fig. 1).

Intravenous methylprednisolone and epinephrine, colloid and crystalloid infusions were performed for treatment of the allergic reaction and hypotension. Despite dopamine perfusion, hypotension of the patient was not recovered. Patient underwent surgery with the preliminary diagnosis of hydatid cyst rupture.

### Operation Report

There was widely dispersed liquid with pus in the abdomen, and sphacelations on the intestines and female vesicles belonging to hydatid cyst in abdomen and in the Douglas pouch, were inspected during the exploration. Abdomen was washed with physiological saline (PS). Perforated cyst content was washed with polyvinylpyrrolidone (PVP) iodine and PS. Cyst wall was debrided and its location area was reduced. Cyst was not communicating with any of organs or bile ducts. Additionally, cysts present at the posterior of the right lobe of liver were aspirated, washed with PS and PVP iodine, and then type I cystectomy was performed (Fig. 2).

Abdomen was washed with a total of 5000 cc PS, after bleeding control one drain was placed in the Douglas pouch and one in the frontal face of perforated cyst passing under the liver was placed. Then abdomen was closed accordingly.

Since no problem was experienced during the postoperative period, drains were removed at the postoperative 3<sup>rd</sup> day, and she was discharged at post op day 5 with 10 mg/kg/day albendazole treatment. The patient had no follow up problem after the 1st month and is still attending the regular follow-up controls.

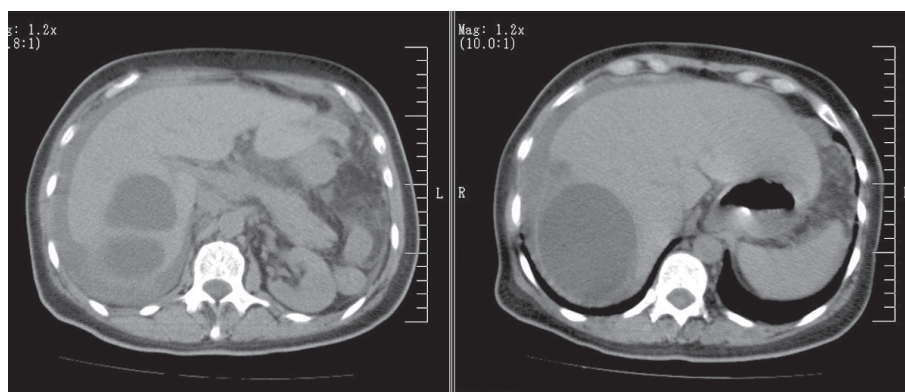
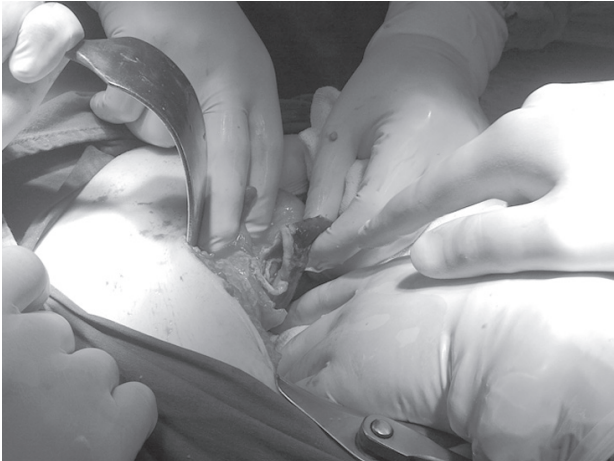

Fig. 1. Abdominal CT image of the patient.



**Fig. 2.** A scene during the operation.

## DISCUSSION

Hydatid cyst is a parasitic and zoonotic disease of animals and human beings. There are 4 subgroups of hydatid cysts, but 2 of them are frequently encountered. These are EG and *E. Multiocularis*. For *Echinococcus* dogs are the main hosts, whereas cattle, sheep, horse and pigs are intermediate hosts. Humans are coincidental hosts that are infected by either contacting with main hosts or eating the contaminated foods. As a result, the eggs that have entered into the body open at the duodenum. The released embryos reach lungs and liver through portal or lymphatic systems after perforating the intestinal wall, and there they form the hydatid cyst lesions. Embryos, which surpass hepatic or pulmonary capillary barriers, can involve all organs and structures of the body. In adults, hydatid cysts are located most frequently in the liver, whereas they are located at lungs in children.<sup>[6-8]</sup>

Hepatic hydatid cyst can persist asymptomatic without rupture for years. Although it can stay asymptomatic even after the rupture, it may cause abdominal pain, dyspnea, jaundice and even anaphylactic shock ending in death, according to the abdominal spaces it opened into.<sup>[9]</sup>

Anaphylaxis is a hypersensitivity reaction, which may have a severe clinical presentation. It may lead to death due to vascular collapse and airway obstruction.<sup>[10]</sup>

Anaphylactoid reactions resemble anaphylaxis clinically but have different pathophysiological mechanisms. Anaphylaxis is sudden onset systematic hypersensitivity reactions, which are caused by mediators released from mast cells and basophiles as a result of IgE mediated immune reactions. If the same clinical presentation is observed by other mechanisms that are not mediated by IgE, they are called as anaphylactoid reactions.<sup>[11]</sup>

It is reported that after the rupture, the mixing of cystic content into systemic circulation can cause anaphylactic reactions in hepatic hydatid cyst cases.<sup>[12]</sup> If hypotension and tachycardia, which are frequently encountered cardiovascular symptoms, are not diagnosed and treated early enough, then severe arrhythmia and cardiovascular collapse can develop rapidly.

Our case has applied with the complaints of hypotension and syncope that are unresponsive to medical treatment. Diagnosis of urticaria depends clinically on characteristics of the lesion: itching, redness (fade out when pressed), papule formation (with fainted centroms) and self-disappearance in a short time. Lesions can be seen at every part of the body. However, their presence in periorbital and perioral areas should remind of angioedema.

Angioedema can involve mucosa. Tongue may be swollen, even very rarely; laryngeal edema and related asphyxia may ensue. There are many responsible factors in etiology. Hydatid cyst rupture is one of the reasons of urticaria. In our case, there are urticarial skin rashes, which have developed within hours.

Diagnosing the hydatid cyst disease is not always easy. Positivity of serological tests does not always indicate the disease presence, whereas their negativity does not also always rule out the disease. Positive results are obtained 50% in pulmonary involvement cases and 5% in hepatic involvements by ELISA or indirect hemagglutination techniques.<sup>[5]</sup>

Radiologic imaging methods have an important place in diagnosing the hydatid cyst; USG and CT are the first preferred methods.<sup>[13]</sup> Specific findings in USG and CT imaginings are female cysts, detached membranes attached to the wall, and hydatid sand.

Ruptured hydatid cysts that have oozed into the abdomen should be washed with salty water and albendazole should be started after the surgery.<sup>[14-16]</sup> We also have washed the abdomen with hypertonic saline solution and later on we have discharged the patient with 10 mg/kg/day albendazole treatment for 3 months.

## CONCLUSION

The case we have presented here emphasizes that hydatid cyst rupture should be included in the differential diagnosis of patients, who apply to the emergency units with complaints of urticaria, hypotension resistant to medical treatment and syncope.

## REFERENCES

1. Kabaalioglu A, Karaali K, Apaydin A, et al. Ultrasound-guided percutaneous sclerotherapy of hydatid liver cysts in children. *Pediatr Surg Int* 2000;16:346-50.
2. Esmel H, Şahin DA. Treatment of pulmonary hydatid cysts: Review. *Türkiye Klinikleri J Med Sci* 2007;27:870-5.
3. Bektaş A, Örmeci N. Complications of hydatid cyst disease and peritoneal hydatid cyst. *Türkiye Klinikleri J Surgery* 1998; 3 (3): 199-201.
4. Yüceyar L, Demirok M, Özdilmaç İ, et al. Anaphylaxis in patients having thoracotomy due to pulmonary hydatid cyst. *Solunum* 2004;6:235-38.
5. Morar R, Feldman C. Pulmonary echinococcosis. *Eur Respir J* 2003;21:1069-77.
6. Beggs I. The radiology of hydatid disease. *AJR Am J Roentgenol* 1985;145:639-48.
7. Cangir AK, Sahin E, Enön S, et al. Surgical treatment of pulmonary hydatid cysts in children. *J Pediatr Surg* 2001;36:917-20.
8. Sahin E, Kaptanoğlu M, Nadir A, et al. Traumatic rupture of a pulmonary hydatid cyst: a case report. *Ulus Travma Acil Cerrahi Derg* 2006;12:71-5.
9. Boyano T, Moldenhauer F, Mira J, et al. Systemic anaphylaxis due to hepatic hydatid disease. *J Investig Allergol Clin Immunol* 1994;4:158-9.
10. Karaman Ö, Köse S. Anaphylaxis. *Klinik Pediatri* 2003;2:89-97.
11. Johansson SG, Bieber T, Dahi R, et al. Revised committee of the world allergy. *J Allergy Clin Immunol* 2004;113:832-6.
12. Taşpınar V, Erdem D, Erk G, et al. Intraoperative anaphylaxis caused by a hydatid cyst: Case report. *Türkiye Klinikleri J Anest Reanim* 2004;2:36-40.
13. Akhan D, Çakmakçı M, Göçmen A, et al. Novelty in hydatid cyst disease. *Hacettepe Tıp Dergisi* 1996;1:52-7.
14. Teggi A, Giattino M, Franchi C, et al. A hypothesis on the significance of an increase in serum transaminases in patients with hydatidosis treated with benzimidazol carbamates. *Recenti Prog Med* 1997;88:452-8.
15. Magambo JK, Zeyhle E, Ngenda NT, et al. Echinococcus granulosus: Ultrastructural effect of albendazole therapy. *Afr J Health Sci* 1994;1:169-74.
16. Ertekin C, Aksu KI. Emergency surgical interventions in hydatid cyst disease. *Türkiye Klinikleri J Gen Surg-Special Topics* 2010;3:56-9.