



Burned-Out Tumor of the Undescended Testis: A Rare Cause of Intra-Abdominal Mass in Childhood

Çocukluk Çağının Nadir Bir Karın İçi Tümörü Sebebi: İnmemiş Testisin Burned-Out Tümörü

Ünal Bakal¹ , Mehmet Ruhi Onur² , Mehmet Saraç¹ , Tugay Tartar¹ , Olgun Konaş³ , Ahmet Kazez¹

Abstract/Öz

Germ cell tumors may manifest as a burned-out testis tumor in the abdomen that is characterized by lymph node metastasis or another manifestation of a metastatic neoplasm with a partially or totally histologically regressed, occult primary tumor in the testis. An 8-month-old boy presented with abdominal mass and hypospadias. On physical examination, a palpable abdominal mass in the left abdomen, the absence of the left testis in the scrotum, and hypospadias were found. Color flow Doppler ultrasonography revealed a well-defined, hypoechoic mass with no vascular flow. A laparoscopy was performed. No testis was found in the inguinal region and the abdomen. An amputated, smooth surface with brown color mass was found in the retrovesical area of the peritoneum. The mass was removed, and macroscopic examination of the lesion yielded a well-defined, stone hard mass. No live tissue was found histopathologically. Immunohistochemical studies revealed relatively positive findings for germ cell tumor. To our knowledge, this case report is the first burned-out germ cell tumor that developed in the undescended testis in children. Here, we present the clinical and imaging findings of a burned-out germ cell tumor of the undescended testis.

Keywords: Undescended testis, germ cell tumor, burned-out tumor, ultrasonography, magnetic resonance imaging

Burned-out tümörü, testiste germ hücreli tümörün kısmen yada tamamen gerilemesiyle ortaya çıkan bir durumdur. Klinik olarak lenf nodu metastazı yada metastatik bir neoplazmin başka bir bulgusunun saptanması ile tanımlanabilir. Sekiz aylık erkek hasta karın ağrısı ve hipospadias şikayeti ile polikliniğimize başvurdu. Fizik muayenesinde karnın sol tarafında ele gelen kitle, skrotumda sol testisin ele gelmemesi ve hipospadias bulguları mevcuttu. Renkli doppler ultrasonografide vasküler akımın alınmadığı hipoeoik kitle tanımlandı. Laparoskopide inguinal bölgede ve karn içerisinde sol testisin olmadığı görüldü. Ancak retrovezikal alanda kahve renkli, düzgün yüzeyli ve sert kıvamda kopmuş bir kitle görüldü ve çıkarıldı. Histopatolojik incelemede canlı doku yoktu. İmmünohistokimyasal çalışmada ise germ hücreli tümör olarak değerlendirildi. Olgumuz çocuklarda inmemiş testiste gelişen ilk burned out germ hücreli tümördür. Biz bu olgu sunumunda inmemiş testiste gelişen burned out germ hücreli tümörün klinik ve radyolojik görüntülerini sunmayı amaçladık.

Anahtar Kelimeler: İnmemiş testis, germ hücreli tümör, burned-out tumor, ultrasonografi, manyetik rezonans görüntüleme

Introduction

Intra-abdominal masses are not infrequently encountered in children. Clinical evaluation and treatment plan depend on the characterization of these masses. Cystic intra-abdominal masses are usually benign. The risk of malignancy increases in solid intra-abdominal masses. Characterization of solid intra-abdominal masses and determination of the origin of these masses with imaging techniques are important before planning treatment.

Intra-abdominal solid masses most frequently originate from organs that are normally localized in the abdomen. As an exception, tumors resulting from the undescended testis may manifest as intra-abdominal mass. The most frequent tumor type arising from the undescended testis is germ cell tumor. Germ cell tumors may manifest as a burned-out testis tumor that is characterized by lymph node metastasis or another manifestation of a metastatic neoplasm with a partially or totally histologically regressed, occult primary tumor in the testis. As first defined by Prym, all burned-out testis tumors were described as a regressed tumor in the normal or the undescended testis with metastasis (1). To the best of our knowledge, the occurrence of burned-out testis tumor in the undescended testis without metastasis was not reported before in previous studies. In this case report, we present the clinical and imaging findings of a burned-out germ cell tumor of the undescended testis.

Case Report

Parental written informed consent was obtained from the parents before patient participation in this case study. An 8-month-old boy presented with abdominal mass and hypospadias. On physical examination, a palpable abdominal mass in the left abdomen, the absence of the left testis in the scrotum, and hypospadias were found. Other examination findings were

This study was presented as a poster at 32nd National Pediatric Surgery Congress, September 17-20 2014, Trabzon, Turkey

ORCID IDs of the authors: Ü.B. 0000-0002-5140-8618; M.R.O. 0000-0003-1732-7862; T.T. 0000-0002-7755-4736; O.K. 0000-0002-1372-1128; A.K. 0000-0003-0440-3555; M.S. 0000-0002-6660-5243.

¹Department of Pediatric Surgery, Firat University School of Medicine, Elazığ, Turkey

²Department of Radiology, Hacettepe University School of Medicine, Ankara, Turkey

³Department of Pathology, Erciyes University School of Medicine, Kayseri, Turkey

**Address for Correspondence/
Yazışma Adresi:**
Tugay Tartar
E-mail: tugaytartar@gmail.com

Received/Geliş Tarihi: 07.12.2017
Accepted/Kabul Tarihi: 25.02.2018

© Copyright 2018 by Available online at
istanbulmedicaljournal.org

© Telif Hakkı 2018 Makale metnine
istanbultipdergisi.org web sayfasından
ulaşılabilir.

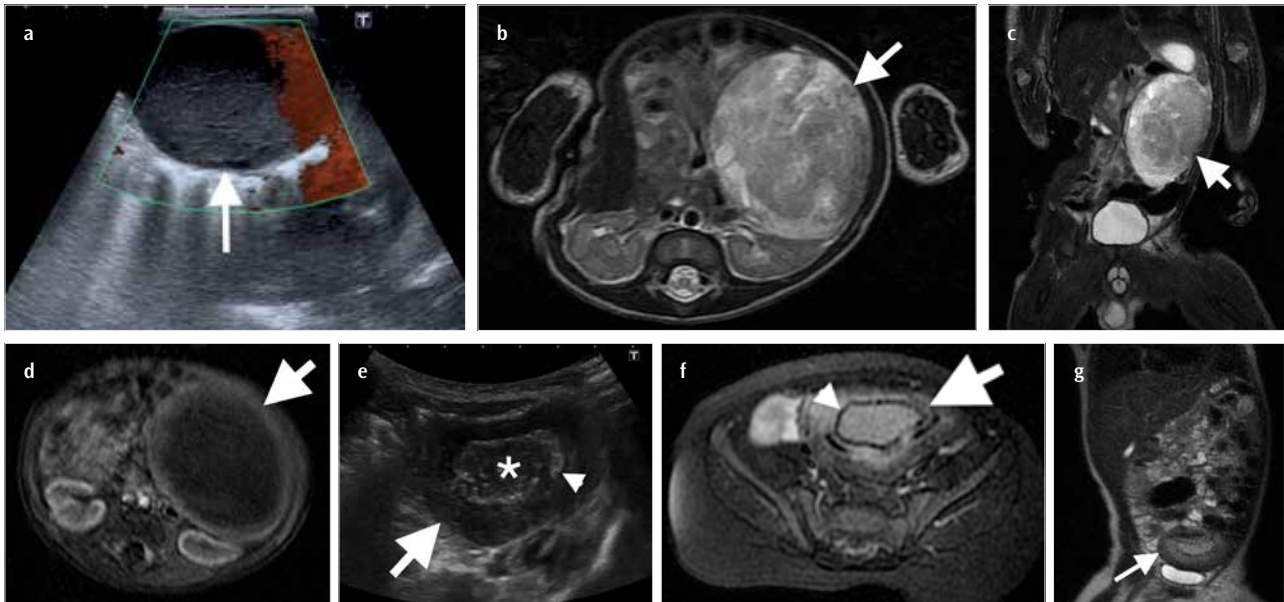


Figure 1. a-g. Burned-out testis tumor in the undescended testis. (a) Power Doppler US demonstrates a well-defined hypoechoic mass (arrow) with no vascular flow. Axial (b) and coronal (c) T2-weighted MR images reveal a well-defined heterogeneous hyperintense mass (arrows) anterior to the left kidney compressing the left kidney and bowels. (d) Axial unenhanced T1-weighted MR image demonstrates peripherally hyperintense centrally hypointense mass (arrow). (e) Gray scale US reveals a solid mass with hypoechoic appearance peripherally (arrow). A hyperechoic rim (arrowhead) representing calcification encircles the central hypoechoic necrotic area (*). (f) Axial T1-weighted fat saturated MRI demonstrates a centrally hyperintense pelvic mass (arrow) with a hypointense rim (arrowhead) that represents calcification. (g) Coronal T2-weighted MRI reveals a mass (arrow) superior to the bladder with peripherally hypointense and centrally hyperintense components that represent fibrous capsule and necrosis, respectively.

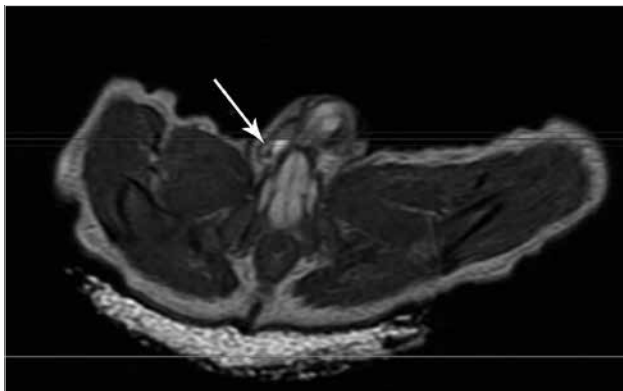

Figure 2. Axial MR image. The right testicle in the normal localization, the right testicular vessels, and the ductus structures are monitored in the right inguinal canal.

repeated MRI of the patient obtained 6 months after the initial presentation revealed a 35×57 mm mass in the pelvis just superior to the bladder. Alteration of the signal intensity of the mass on recent MRI was accompanied by size changes in comparison with previous MRI. The mass appeared hypointense on T1-weighted and T2-weighted images centrally. A hypointense rim on T1-weighted and T2-weighted images, which was supposed to represent calcification, was observed (Figure 1e-g). The right testicle, the structure of the right testicular vessels, and the ductus were evaluated as normal on the MRI of the patient (Figure 2). However, it was determined that the left testicle, the structure of the left testicular vessels, and the ductus did not enter into the inguinal canal. The accuracy of these findings was confirmed by laparoscopic exploration. On laparoscopic evaluation, no dysgenetic gonad structure was found. Laparoscopy was performed in order to remove the mass and to find the left testis in the inguinal region or the abdomen. No testis was found during laparoscopy in the inguinal region and the abdomen. An amputated, smooth surface with brown color mass was found in the retrovesical area of the peritoneum. The mass was removed, and macroscopic examination of the lesion yielded a well-defined, stone hard mass (Figure 3a). Umbilical port incision was expanded as much as the size of the mass (3 cm), and the mass was removed with the aid of a clamp. No live tissue was found histopathologically. All the tissue was necrotic and heavily calcified (Figure 3b). Immunohistochemical studies revealed relatively positive findings for germ cell tumor that was stained positive with pancytokeratin, CD117, and human chorionic gonadotropin, but there is no good staining with any antibody due to necrotic and calcified tissues (Figure 3c). The patient was discharged from the hospital with no complication, and repeated imaging and laboratory control studies yielded no positive finding to indicate the recurrence of the tumor.

normal. Disorder of sex development was not considered in the physical examination of the patient. Investigation of hormone levels yielded increased alpha-fetoprotein (29.9 ng/mL; normal range: 0-8.2 ng/mL) and CA 19-9 (57.2 ng/mL; normal range: 0-33 ng/mL). Color flow Doppler ultrasonography (US) revealed a well-defined, hypoechoic mass with no vascular flow (Figure 1a). Magnetic resonance imaging (MRI) demonstrated a 45×50×60 mm left abdominal mass compressing the neighboring structures that appear peripherally hyper and centrally hypointense on T1-weighted images and heterogeneously hyperintense on T2-weighted images. No contrast enhancement was observed in the mass (Figure 1b-d). The left testis was not visualized in the inguinal region on US and MRI. Removal of the mass was recommended to the family according to clinical and imaging findings, but the patient's family denied surgery. After 1 month, dynamic MRI was performed, revealing similar findings with no change in size and appearance of the mass. A

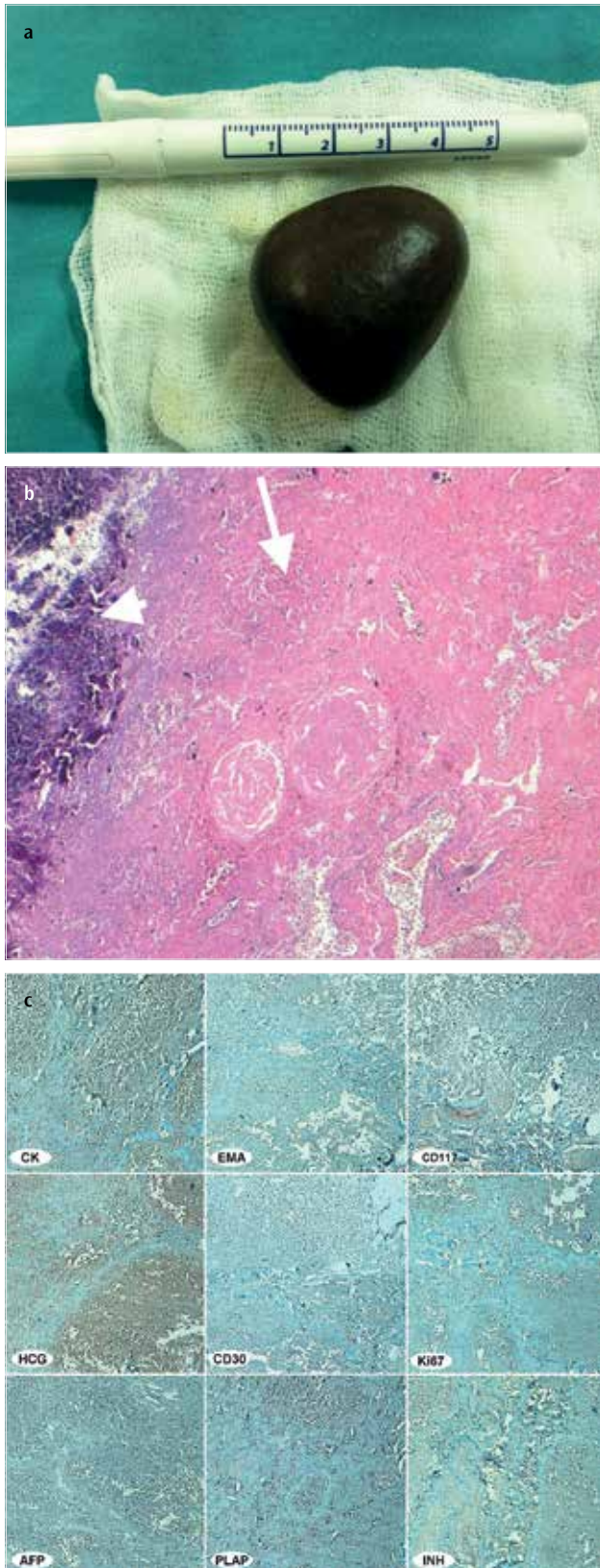


Figure 3. a-c. (a) Burned-out tumor in the undescended testis. Surgical specimen is a well-defined mass with brown color. (b) Excised specimen manifests with irregular calcification (arrowhead) and necrosis (arrow) (a, 4× magnification, hematoxylin and eosin). (c) Immunohistochemistry studies including pancytokeratin, epithelial membrane antigen, CD117, HCG, CD30, Ki67, alpha-fetoprotein, placental alkaline phosphatase, and inhibin stains reveal positive staining for CK, CD117, and HCG, corresponding to germ cell tumor (avidin-biotin peroxidase, 100× magnification).

Discussion

Undescended testis (cryptorchidism) is the most common abnormal condition in newborn males, with an occurrence rate of 1%-6% of full-term neonates and approximately 0.8% of infants at 1 year (2). The inguinal canal is the most frequent site for undescended testis, whereas 8% are located in the abdomen (3). An intra-abdominal testis may be located between the level of the inferior pole of the kidney in the retroperitoneum and the internal inguinal ring. Cryptorchidism may remain as a non-complicated testis in the abdomen or manifest with malignancy. The risk of testicular cancer in patients with cryptorchidism is 3% to 5%, leading to a 4- to 7-fold increase compared with the risk of 0.3%-0.7% in the healthy population. A history of an undescended testis is found in 3.5%-14.5% of patients with testicular tumors (4).

Germ cell tumor is the most frequent type of testicular cancer in cryptorchidism. Germ cell tumors arising from the undescended testis may mimic other solid masses in the abdomen in childhood. Retroperitoneal germ cell tumors are classified into metastatic germ cell tumors from primary testicular germ cell tumor and primary extragonadal germ cell tumor. Abdominal germ cell tumors usually appear as a bulky mass with various sizes that represent conglomerated metastatic lymph nodes or primary extragonadal germ cell tumor. In our case report, a germ cell tumor originated from the undescended testis that was localized in the left upper abdomen. The absence of the left testis in the scrotum was helpful in the diagnosis of the undescended testis tumor before surgery. The difference of our case from other germ cell tumors of the undescended testis was regression and mobilization of the primary tumor within 8 months, which can be explained by the “burned-out” phenomenon of testis tumors.

Burned-out testis tumor refers to a germ cell tumor in the extragonadal tissues with the presence of spontaneously regressed tumor in the testis. Metastasis of burned-out tumor may occur in the retroperitoneum, mediastinum, lymph nodes, lungs, and liver. Sonographic features of burned-out testis tumors include hyperechoic, sometimes calcified area, corresponding to the tumoral scar with or without a neighboring hypo or hyperechoic area that represents residual tumor. Histopathological features of burned-out testis tumor include hyalinization, interstitial fibrosis, necrosis, deposits of calcification, hemosiderin, intratubular hematoxyphilic and psammoma bodies, sclerosis of the seminiferous tubules, and rare inflammatory cells. Although indistinct lesions may be encountered on the testis, US diagnosis of burned-out testis tumors is usually made with the detection of large metastatic lesions in the abdomen. The occurrence of burned-out testis tumor is unclear, but suggested mechanisms include a tumoral tendency to spontaneous necrosis secondary to increased metabolic activity, immune, and vascular mechanisms (5).

Immune mechanism implies the stimulation of the immune system by malignant cells in the blood in the setting of metastasis that was protected by the blood-testis barrier when localized only in the testis. Lymph node metastasis occurs before the establishment of full immune-escape mechanisms. Tumor cells become visible to professional antigen-presenting cells for induction of adaptive immunity that results in the regression of the primary tumor (6). Lehmann and Muller reported a case in which immunohisto-

chemical examination of the testicular biopsy showed intracellular and membranous accumulation of antibody in the atypical spermatogonia (7). These specific antibodies were found only in the patient's serum, not in 500 control sera. The vascular theory suggests that tumor regression occurs secondary to decreased vascular flow, resulting from a high metabolic rate of the tumor outgrowing its blood supply (8). We suggest that the imaging findings of our case support the vascular hypothesis in burned-out testicular tumors. The intra-abdominal germ cell tumor of our case regressed in size, became necrotic, and dropped in the pelvic cavity from the upper quadrant with time, suggesting secondary to vascular flow depletion. The tumor in our patient was enhanced with gadolinium on contrast-enhanced MRI at its primary site; however, a second MRI, which revealed a drop in mass in the pelvic cavity, demonstrated no enhancement, suggesting loss of vascular flow in the mass. Diminished vascular flow would prevent the tissue bonding of tumor with neighboring structures, resulting in decreased tumor size, unbounded mass, and localization change in the abdomen.

Intra-abdominal masses in children may remain asymptomatic until they became large enough to cause pain or mass effect on neighboring organs. US, which is preferred as an imaging technique in childhood due to lack of ionizing radiation and contrast material, can demonstrate various pathologies owing to diminished body thickness in children. Computed tomography and MRI can both detect and characterize retroperitoneal masses and serve as an aid in imaging modalities before planning treatment of neoplastic masses. In our case, US and MRI were used as follow-up imaging modalities, which were helpful by revealing size and localization change of the tumor and absence of the left testis in the scrotum.

Differential diagnosis of intra-abdominal masses in children includes lymphoma, neuroblastoma, sarcoma, metastasis of germ cell tumor, and primary extragonadal germ cell tumor. Since most of the solid retroperitoneal tumors have malignant potential, detection and characterization of these masses with appropriate imaging techniques are important for preoperative evaluation. The absence of the testis in the scrotum, which was confirmed by imaging techniques and laparoscopic investigation, alteration of size, and localization of the mass suggested burned-out germ cell tumor of the undescended testis in our case. Regression of an intra-abdominal mass is a well-known feature of stage 4S neuroblastoma in children. However, stage 4S neuroblastoma presents with distant metastases, and no localization alteration was reported for neuroblastoma in the literature (9). Spontaneous regression of tumor has also been described in renal cell and breast carcinoma, lymphoma, and malignant melanoma, which occur rarely in the age group of our patient (10).

Conclusion

To our knowledge, our case report is the first burned-out germ cell tumor that developed in the undescended testis. We suggest that the burned-out phenomenon may occur in the primary undescended testis tumors even in the absence of metastasis. Size and localization change in an abdominal mass may be encountered due to regression and necrosis in a burned-out tumor of the undescended testis.

Informed Consent: Written informed consent was obtained from parents of the patients who participated in this study.

Peer-review: Externally peer-reviewed.

Author Contributions: Concept - Ü.B.; Design - Ü.B., M.R.O. O.K.; Supervision - M.S., T.T., A.K.; Data Collection and/or Processing - Ü.B., M.S., T.T.; Analysis and/or Interpretation - M.S., A.K.; Literature Search - M.R.O., T.T., O.K.; Writing Manuscript - Ü.B., M.R.O.; Critical Review - A.K., O.K.

Conflict of Interest: The authors have no conflict of interest to declare.

Financial Disclosure: The authors declared that this study has received no financial support.

Hasta Onamı: Yazılı hasta onamı bu çalışmaya katılan hastanın ailesinden alınmıştır.

Hakem Değerlendirmesi: Dış Bağımsız.

Yazar Katkıları: Fikir - Ü.B.; Tasarım - Ü.B., M.R.O. O.K.; Denetleme - M.S., T.T., A.K.; Veri Toplanması ve/veya - Ü.B., M.S., T.T.; Analiz ve/veya Yorum - M.S., A.K.; Literatür Taraması - M.R.O., T.T., O.K.; Yazıyı Yazan - Ü.B., M.R.O.; Eleştirel İnceleme - A.K., O.K.

Çıkar Çatışması: Yazarların beyan edecek çıkar çatışması yoktur.

Finansal Destek: Yazarlar bu çalışma için finansal destek almadıklarını beyan etmişlerdir.

References

- Peroux E, Thome A, Geffroy Y, Guema BN, Arnaud FX, Teriitehau CA, et al. Burned-out tumour: A case report. *Diagn Interv Imaging* 2012; 93: 796-8. [\[CrossRef\]](#)
- Friedland GW, Chang P. The role of imaging in the management of the impalpable undescended testis. *AJR Am J Roentgenol* 1988; 151: 1107-11. [\[CrossRef\]](#)
- Nguyen HT, Coakley F, Hricak H. Cryptorchidism: strategies in detection. *Eur Radiol* 1999; 9: 336-43. [\[CrossRef\]](#)
- Woodward PJ. Case 70: seminoma in an undescended testis. *Radiology* 2004; 231: 388-92. [\[CrossRef\]](#)
- Kontos S, Doumanis G, Karagianni M, Politis V, Simaioforidis V, Kachrilas S, et al. Burned-out testicular tumor with retroperitoneal lymph node metastasis: a case report. *J Med Case Rep* 2009; 3: 8705. [\[CrossRef\]](#)
- Curigliano G, Magni E, Renne G, De Cobelli O, Resciqno M, Torrissi R, et al. "Burned out" phenomenon of the testis in retroperitoneal seminoma. *Acta Oncol* 2006; 45: 335-6. [\[CrossRef\]](#)
- Lehmann D, Müller H. Analysis of the autoimmune response in an 'in situ' carcinoma of the testis. *Int J Androl* 1987; 10: 163-8. [\[CrossRef\]](#)
- Balalaa N, Selman M, Hassen W. Burned-out testicular tumor: a case report. *Case Rep Oncol* 2011; 4: 12-5. [\[CrossRef\]](#)
- Shah RU, Lawrence C, Fickenscher KA, Shao L, Lowe LH. Imaging of pediatric pelvic neoplasms. *Radiol Clin North Am* 2011; 49: 729-48. [\[CrossRef\]](#)
- Saleh FH, Crotty KA, Hersey P, Menzies SW, Rahman W. Autonomous histopathological regression of primary tumours associated with specific immune responses to cancer antigens. *J Pathol* 2003; 200: 383-95. [\[CrossRef\]](#)

Cite this article as: Bakal Ü, Onur MR, Saraç M, Tartar T, Konaş O, Kazez A. A Rare Cause of Intraabdominal Mass in Childhood: Burned-Out Tumor of Undescended Testis. *Istanbul Med J* 2018; 19 (3): 273-6.