



# Tracheobronchial Amiloidosis

Soner Demirbaş<sup>1</sup>, Orkide Kutlu<sup>2</sup>, Abdullah Sakin<sup>3</sup>

## Abstract

Localized pulmonary amyloidosis without systemic involvement differentiates as nodular parenchymal opacities, diffuse parenchymal opacities, or tracheobronchial amyloidosis (TBA). TBA is a condition mostly seen in males aged up to 50–60 years, accounting for approximately 1% of benign lesions in the tracheobronchial tree. TBA is characterized by the accumulation of the amyloid material comprising immunoglobulin light chain (AL), which are observed as submucosal plaques and/or polypoid tumors; progressive form of tracheobronchial amyloidosis can lead to airway obstruction. Repeated excisional treatments, mainly laser treatment is preferable to open surgery. Here, we have presented the case of a patient diagnosed with the rarely occurring localized TBA.

**Keywords:** Amyloidosis, pulmonary, tracheobronchial

## Introduction

Amyloidosis is a condition in which organ dysfunction associated with structural disruption in tissues occurs because of the accumulation of fibrillary insoluble proteins as beta-folded layers in the extracellular area. In amyloidosis, the involvement of the respiratory tract is rare and it occurs as a component of a systemic disease or as a localized involvement. Localized pulmonary amyloidosis can develop in three forms: nodular parenchymal opacities, diffuse parenchymal opacities, or tracheobronchial involvement (1).

Tracheobronchial amyloidosis (TBA) accounts for 1% of benign lesions in the tracheobronchial tree and can cause airway obstruction because of progressive disease (2). In this study, a male patient who was diagnosed with rarely observed localized TBA was presented.

## Case Report

A 59-year-old male patient was admitted because of complaints of dyspnea, cough, sputum, fever, night sweating, and chest pain. He stated that these complaints, which had lasted for 13 years at intervals, had increased after an upper respiratory tract infection approximately 1 month ago. His arterial blood pressure was 120/80 mmHg, pulse rate was 80/min, and fever was 36.2°C. During physical examination, respiratory sounds were decreased in the right basal. The results of other systemic examinations were normal. The values of the hemogram, urinary analysis, fasting blood glucose, urea, creatinine, electrolytes, liver enzymes, c-reactive protein (CRP), and sedimentation rate were within normal ranges. No acid-resistant bacillus was found in the bronchial lavage and morning sputum specimen, which were evaluated three times. Respiratory function test revealed FVC as 78%, FEV<sub>1</sub> as 94%, and FEV<sub>1</sub>/FVC as 98. In the PA chest radiography, there was a band of gray shade adjacent to the diaphragm in the lower zone of the right lung (Figure 1). In the computed tomography (CT) of the thorax, there were obstructions in the lower lobe base of the right lung, superior segment bronchia, and the right main bronchus. Furthermore, there were inflammatory changes in the lower lobe medial base of the right lung and superior posterior segments, which appeared consistent with pneumonia. Moreover, lymph nodes, of which the largest was 13×6 mm in size and which was localized in the sub-carina, were observed in the mediastinum. In bronchoscopy, white nodular lesions, which were rich in terms of vascular structures, were found in the trachea and in both the main bronchi, upper and medial lobe bronchi (Figure 2). The left upper lobe separation carina was expanded, and the mucosa was edematous. The left lower lobe bronchial carina was concentrically light, and the right lower lobe bronchial orifice was narrowed at the rate of 80%. Moreover, the mucosa was irregular and edematous. In the forceps biopsy samples taken from this area, the accumulations of acellular eosinophilic homogenized material were locally observed in addition to granuloma structures, including giant cells. This substance was evaluated as amyloidosis because it demonstrated a positive expression with cresyl violet and

This study was presented at the 11<sup>th</sup> Uludağ Internal Medicine Winter Congress, 8-11 March 2015, Bursa, Türkiye.

<sup>1</sup>Department of Chest Diseases, Necmettin Erbakan University Meram Faculty of Medicine, Konya, Türkiye

<sup>2</sup>Clinic of Internal Medicine, Konya Training and Research Hospital, Konya, Türkiye

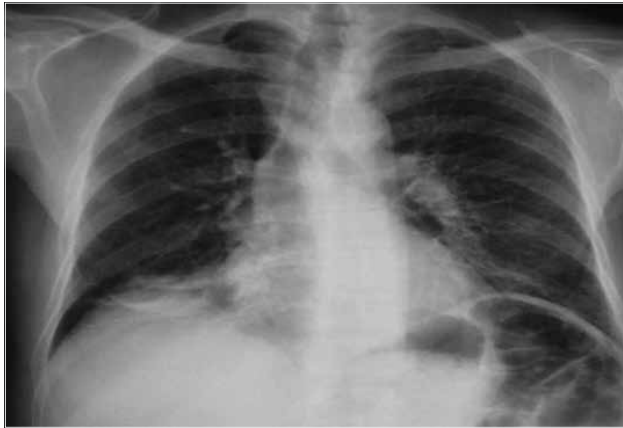<sup>3</sup>Clinic of Medical Oncology, Okmeydanı Training and Research Hospital, Istanbul, Türkiye

**Address for Correspondence:**  
Orkide Kutlu  
Phone: +90 507 241 49 49  
E-mail: orkidekutlu@windowslive.com

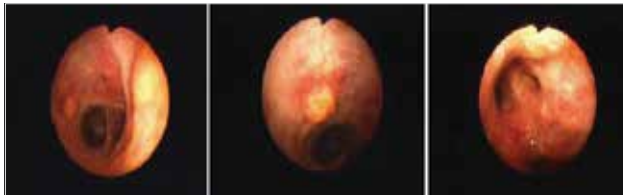
Received:  
22.02.2015

Accepted:  
18.05.2015

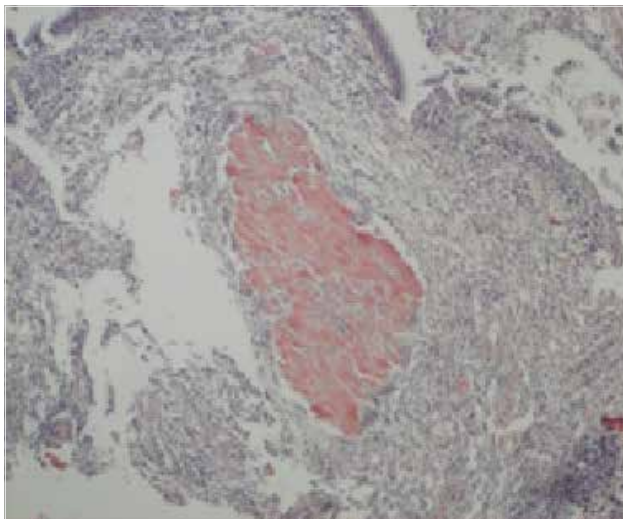
© Copyright 2015 by Available online at  
www.istanbulmedicaljournal.org



**Figure 1.** In PA chest radiography, a band of gray shade adjacent to the diaphragm in the base of the right lung



**Figure 2.** Diffuse nodular deposits in the trachea and both bronchial mucosae and concentric narrowing in the lower lobe bronchus



**Figure 3.** Amyloid material stained with Congo red; Congo red 100x

Congo red (Figure 3). No organomegaly was found in the abdominal ultrasonography.

## Discussion

Systemic amyloidosis primarily develops because of the storage of immunoglobulin light chain (AL protein), which resulted from plasma cell dyscrasias. Secondarily, it occurs because of the deposit of hepatic-origin serum amyloid A that is associated with chronic inflammatory/autoimmune diseases (such as bronchiectasis, tuberculosis, sarcoidosis, cystic fibrosis, and collagen vascular diseases). The protein accumulating in localized pulmonary amyloidosis is the immunoglobulin light chain (AL), the deposit of monoclonal proteins released from plasma cells around the le-

sion plays a role in its pathogenesis. Monoclonal light chains are not observed in the circulation, and they do not accumulate in a region except in the targeted organ. These structures reveal a green birefringence under polarized light microscope after Congo red staining. In immunohistochemical examination, they are not stained with anti-Kappa; however, they are stained with anti-lambda light chain antibodies (3).

Tracheobronchial amyloidosis is a condition that is commonly observed among males in the 5<sup>th</sup> or 6<sup>th</sup> decades (4). It is characterized by the accumulation of amyloid material as a localized, diffuse, or multifocal form in submucosal plaques and/or polypoid tumors. Morbidity and mortality are directly associated with the amount of amyloid accumulated in the airways. Death occurs because of progressive bronchial obstruction and respiratory failure. The disease can be completely asymptomatic or dyspnea, wheezing, hemoptysis, recurrent pneumonia, cough, and atelectasis can be observed (3). In our case, diffuse submucosal nodule structures were found, and the patient had complaints of dyspnea and chest pain.

The localized form of TBA can present with three patterns of involvement as follows: proximal, middle/main bronchial, or distal type. Proximal or upper tracheal disease can require tracheotomy because of the risk of respiratory failure and upper airway obstruction that is associated with progressive disease. Middle and distal tracheal or main bronchial disease can lead to lobar collapse or recurrent parenchymal infections, serious obstruction in the main bronchus, and respiratory failure. In contrast, distal airway disease can present with recurrent pneumonia, cough, and bronchiectasis. TBA can mimic bronchial asthma because of its non-specific symptoms (3).

Radiography, CT, respiratory function tests, bronchoscopy, and biopsy are used for diagnosis. Endobronchial form is not associated with systemic disease. Therefore, there is no requirement for planning expensive/invasive advanced examinations for systemic amyloidosis findings. The results of chest radiographies are normal in half of the patients; however, atelectasis or vascular collapse, calcifications, bronchiectasis or hilar/mediastinal lymphadenopathies can be observed in other patients. In CT, thickening of the airway, irregular narrowing of the lumen, and calcifications are remarkable (3). In our patient, the band of gray shade in the chest radiography was consistent with possible atelectasis, and there were narrowing of the bronchial lumens, inflammatory changes, and large lymph nodes in the mediastinum in CT. The final diagnosis was established through biopsy that was obtained from diffuse nodular lesions observed in bronchoscopy.

Treatment must be planned considering the degree of obstruction. While there is no requirement for treatment in asymptomatic patients, aggressive local/systemic treatments must be performed when obstruction is more obvious. In TBA, the standard treatment is excisional therapies. The standard treatment for upper and middle airway diseases is bronchoscopic debridement with forceps, and repeating procedures are often required. In some nodular TBA, carbon dioxide or neodymium-doped yttrium aluminum garnet laser treatment removes the tissue and inhibits the formation of new amyloid deposits because of thermally damaged plasma cells in that area. After performing local resection, a silicon stent can be placed for preventing recurrent obstruction (5).

Repeating bronchoscopic implementations should be preferred over open surgery because they are safer. Because plasma cells are radiosensitive, isolated cases have been treated with radiotherapy, and it has been stated that performing a tracheostomy is another treatment alternative to preserve airway patency when necessary (3). Treatments conducted with colchicine, oral glucocorticoids, and iodine isoform of doxorubicin have failed. Systemic chemotherapy should not be used because of the low number of clonally increased plasma cells and toxic side effects. In a study, localized tracheobronchial B cell clonal expression was demonstrated as molecular firstly and treatment was attempted using anti-CD20 monoclonal antibody rituximab, which was a B cell-targeted therapy (6).

In supportive care, it must be aimed to decrease the production of mucus for increasing airway lumen patency. When necessary, antibiotics, regular use of nebulizer, and occasional use of oral/inhaled glucocorticoid can be considered as adjuvant therapies to debridement.

## Conclusion

The prognosis of localized pulmonary amyloidosis is highly good. In a series, it has been reported that death occurs in approximately 9 years in patients with isolated pulmonary and tracheobronchial disease (7). In contrast, the mean lifetime is 16 months in patients with systemic amyloidosis with lung involvement (8). Pulmonary amyloidosis must be considered in the differential diagnosis of patients with complaints of dyspnea, cough, sputum, and chest pain and whose complaints do not regress with medical treatment.

**Informed Consent:** Written informed consent was not received due to the retrospective nature of this study.

**Peer-review:** Externally peer-reviewed.

**Author Contributions:** Concept - S.D.; Design - S.D., O.K.; Supervision - S.D., O.S., A.S.; Funding - S.D., O.K.; Materials - S.D., O.K.; Data Collection and/or Processing - S.D., O.K.; Analysis and/or Interpretation - O.K., A.S.; Literature Review - S.D., O.K., A.S.; Writer - O.K., A.S.; Critical Review - O.K., A.S.

**Conflict of Interest:** No conflict of interest was declared by the authors.

**Financial Disclosure:** The authors declared that this study has received no financial support.

## References

1. Berk JL, O'Regan A, Skinner M. Pulmonary and tracheobronchial amyloidosis. *Seminars in respiratory and critical Care Medicine* 2002; 23: 155-65. [\[CrossRef\]](#)
2. Şen E, Kaya A, Kılıçkap M, Ülger F, Ereku S, Kervancıoğlu C ve ark. Akciğer tutulumu Olan Sistemik Amiloidoz Olgusu. *Klinik Sorunlar* 2008; 9: 181-4.
3. Serraj M, Kamoui I, Znati K, Kouara S, Sahnoune F, Amara B, et al. Pseudotumoral tracheobronchial amyloidosis mimicking asthma: a case report. *J Med Case Rep* 2012; 6: 40. [\[CrossRef\]](#)
4. Şenol T, Günay Ş, Eser İ, Erkilet E. Trakeobronşial amiloidoz olgusu. *Dicle Tıp Dergisi* 2014; 41: 581-4.
5. Fiorelli A, Accardo M, Galluccio G, Santini M. Tracheobronchial Amyloidosis treated by endobronchial laser resection and self expanding Y stent. *Arch Broncopneumol* 2013; 49: 303-5.
6. Borie R, Danel C, Molinier-Frenkel V, Prevot G, Deslee G, Debray MP, et al. Tracheobronchial amyloidosis: evidence for local B-cell clonal expansion. *Eur Respir J* 2012; 39: 1042-5. [\[CrossRef\]](#)
7. O'Regan A, Fenlon HM, Beamis JF Jr, Steele MP, Skinner M, Berk JL. Tracheobronchial amyloidosis. The Boston University experience from 1984 to 1999. *Medicine* 2000; 79: 69-70. [\[CrossRef\]](#)
8. Yüksekol İ, Balkan A, Taşan Y, Deveci S, Kaya A, Demirci N. Bir Pulmoner Parankimal Amiloidozis Olgusu. *Tüberküloz ve Toraks Dergisi* 2001; 49: 489-92.