



Crohn's Disease Presenting as Acute Appendicitis: Case Series

Oğuzhan Dinçel¹, Fatih Başak², Erdem Kınacı³, Bahattin Pektaş¹

Abstract

Objective: Crohn's disease can be observed in younger patients and may present with a clinical condition such as acute appendicitis. In this study, we aimed to investigate acute abdominal conditions that were caused by the first attack of Crohn's disease.

Methods: Patients who were admitted with the signs of acute abdomen and underwent surgery between 2009 and 2013 were included in the study. Patients diagnosed with Crohn's disease based on intraoperative findings and postoperative evaluations were included in the study. Patient demographics, findings about Crohn's disease, and follow-up data were recorded.

Results: During the study period, 736 patients who had acute abdomen and a preliminary diagnosis of acute appendicitis were operated, and four of them (0.5%) were diagnosed with Crohn's disease at the peroperative or postoperative period. Two of the patients were male and the others were female; the mean age was 36 years (28-45 years). Perioperative inflammatory cecal mass and local abscesses were observed in one patient and drainage was performed. Only appendectomy was performed in the other three patients, and postoperative enterocutaneous fistula was observed in two of them. Intestinal resection was performed in one of the patient with fistula, and the other responded well to medical treatment.

Conclusion: Crohn's disease may present as acute abdomen. Particularly, people without a history of the illness may come to us with such a clinical condition in the first episode; therefore, this situation should not be ignored.

Keywords: Crohn's Disease, acute appendicitis, acute abdomen

Introduction

Crohn's disease (CD) is an idiopathic, chronic inflammatory process, which is most frequently seen in the ileum, and can affect any part of the gastrointestinal tract from the mouth to anus. Individuals with this condition may experience frequent symptomatic relapses and remissions. It can cause various symptoms, including abdominal pain, diarrhea, and growth disorders. Patients' complaints might be similar to the symptoms of abdominal diseases such as tuberculosis, ulcerative colitis, and irritable bowel syndrome (1, 2).

It is difficult to establish a final diagnosis for CD, but there are many diagnostic methods and devices to support the existence of the disease. Physical examination, laboratory tests, imaging studies, and endoscopic examinations are helpful for diagnosis (2). Conservative medical treatments are generally used, but some cases may require surgery, especially cases with intestinal obstruction, perforation, abscess, and fistula formation (3, 4).

In cases diagnosed with acute abdomen and patients undergoing surgery for suspected acute appendicitis, in case of CD, there might be some reservations to perform appendectomy, but sometimes it might be the first signs of clinical CD. In this study, we aimed to investigate cases who had not been previously diagnosed with CD and cases who presented with acute abdominal conditions that were caused by the first attack of CD using studies from the literature.

Methods

Patients who applied to the emergency surgery department between 01.01.2009 and 31.12.2013 with the diagnosis of acute abdomen and those who had undergone surgery because of suspected acute appendicitis were examined. A provisional diagnosis of acute appendicitis was made on the basis of the clinical and laboratory symptoms of the patients. In the diagnosis period, ultrasonography was performed for suspected patients, whereas computed tomography (CT) was performed in appropriate patients. Patients who had undergone surgery with the diagnosis of acute appendicitis but diagnosed with CD after the surgery formed the working group.

Routine laboratory tests, complete blood count, chemistry panel, liver function tests, inflammatory markers and serologic tests were used to support the diagnosis of CD. Imaging methods such as plain abdominal radiography, CT, and ileocolonoscopy were used.

¹Department of General Surgery, Adıyaman University Faculty of Medicine, Adıyaman, Türkiye

²Clinic of General Surgery, Ümraniye Training and Research Hospital, İstanbul, Türkiye

³Clinic of General Surgery, İstanbul Training and Research Hospital, İstanbul, Türkiye

Address for Correspondence:

Oğuzhan Dinçel, Adıyaman Üniversitesi Tıp Fakültesi, Genel Cerrahi Anabilim Dalı, Adıyaman, Türkiye

Phone: +90 536 601 06 30

E-mail: droguzhandinzel@yahoo.com

Received:
08.10.2014

Accepted:
23.02.2015

The demographic data, preoperative symptoms, physical examination findings, and laboratory data of the patients who were included to the study were recorded. The symptoms that were observed during the surgery and the surgeries that had been performed were examined. Postoperative pathological evaluations, further examinations, and symptoms for the diagnosis of CD were examined.

Results

During the study period, 736 patients with acute abdomen were operated with the provisional diagnosis of acute appendicitis. A total of four (0.5%) patients were diagnosed with CD during the follow-up period (Table 1). Two of the patients were male and two were female, and their age ranged from 28 to 45 years, and the average age was 36 years. Abdominal pain was the main complaint of all the patients. Although their present condition was not as severe as in the past, their anamnesis revealed that they had been having episodes of abdominal pain and intermittent diarrhea. Both patients had nausea and vomiting.

All patients presented clinical signs of acute abdominal pain and abdominal tenderness; defense, rebound, or peritoneal irritation symptoms such as rigidity were in favor of acute appendicitis. No palpable mass or other abnormal symptoms were detected. None of the patients had previous abdominal surgeries. Of the laboratory findings, the mean value for leukocytes was $13.400 \pm 5.600 / \text{mm}^3$. One patient had hypoalbuminemia, and one case had anemia. Abdominal ultrasonography was performed in two patients to support and confirm the diagnosis of acute appendicitis. In one patient, CT was performed as further evaluation, and pericecal abscess and inflammatory mass appearance due to acute appendicitis were observed (Figure 1).

All patients underwent surgery with the provisional diagnosis of acute appendicitis, and the surgeries started with McBurney incision. During the surgery, three patients showed no significant pathology, and only appendectomy was conducted. Acute appendicitis was not considered in the assessment of the specimens and the pathological examination. In one patient, pericecal abscess, thickening in peripheral intestinal segments, and inflammatory bowel mass were observed, and drainage was performed on the

abscess (Figure 2). Following medical therapy, ileocolonoscopy was performed, and ulcers were seen in the terminal ileum.

During the follow-up of the patients who underwent appendectomy, enterocutaneous fistula was detected in two patients when discharge from the incision site was observed. One patient showed improvement by means of supportive care. In the further endoscopic examination, that case was diagnosed with CD. Two months later, the other patient underwent right hemicolectomy, including hemicolectomy of the fistulized area. In the pathological evaluation of the small intestine, it was reported that the inflammatory process was symptomatic of CD. In the late period of the last patient who underwent appendectomy, abscess accumulation in the surgical site developed, and the abscess was drained by the percutaneous method accompanied by imaging. To support the diagnosis after medical treatment, CT and ileocolonoscopy were performed on all patients. Patients were evaluated by the Gastroenterology clinic and were transferred to the related clinic with CD diagnosis for follow-up and treatment.

Discussion

As for disease-specific, CD may hold all layers of the intestine, and also diseased intestinal segments can be found among healthy intestinal segments. In those cases in the early stages, small erosions occur in the intestinal lining (aphthous ulcers). In due course, this erosion expands, deepens, and a scar tissue is formed, and the intestine thickens (1, 2). From the terminal ileum and cecum to the appendix, it may emerge as acute or subacute appendicitis. The clinical images may be inconsistent. As a provisional diagnosis, 85% of patients suffering from the right iliac fossa pain and 25% of patients having chronic pain and palpable mass gives an indication of acute appendicitis (2). The disease is seen in all age groups of both sexes at the same rate (5). In our study, all of our cases presented acute appendicitis-like abdominal pain and complaints. All the cases we presented belonged to the young adult age group and can lead to consider acute appendicitis in favor of preliminary diagnosis.

The first episode of the disease is rarely seen as clinical acute appendicitis. The relationship between appendectomies that were performed in the pediatric period in the literature and CD development in the later period were questioned. It was

Table 1. Crohn hastalarının bulguları ve takipleri

no	Age (years) & Sex	Abnormal laboratory results	Abnormal surgical results/the operation performed	Complications/additional treatments/tests	Postoperative CD diagnosis range	Follow-ups
1	34, male	Leukocyte: 18,700/mm ³ Albumin: 2.1 g/dL	Pericecal abscess inflammatory mass/ abscess drainage	-/- ileocolonoscopy	3 months	Control in the 2 nd year, CT 2 months
2	28, female	Leukocyte: 17,800/mm ³ Hemoglobin: 7 g/dL	-/Appendectomy	Postoperative enterocutaneous fistula/medical support therapy/ileocolonoscopy	3 months	Control in the 8 th month, normal
3	45, male	Leukocyte: 8,800/mm ³	-/Appendectomy	Postoperative enterocutaneous fistula/right hemicolectomy/	2 months	Control in the 1 st year, pathology normal
4	37, female	Leukocyte: 8,300/mm ³	-/Appendectomy	Postoperative intra-abdominal abscess/percutaneous drainage/ ileocolonoscopy	3 months	Control in the 6 th month, normal

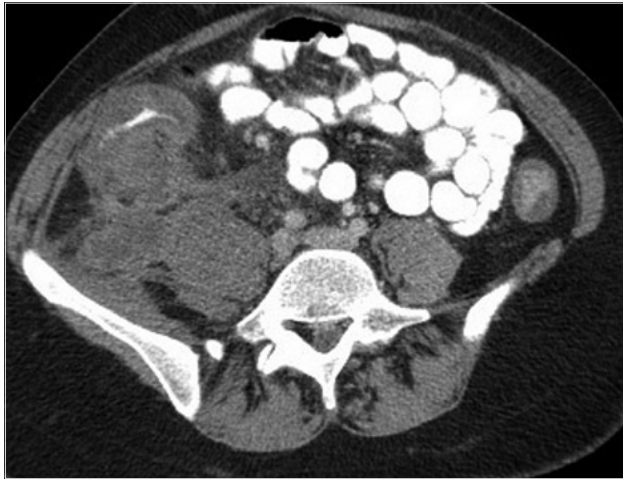

Figure 1. Inflammatory mass and abscess formation around the cecum on computed tomography (CT)

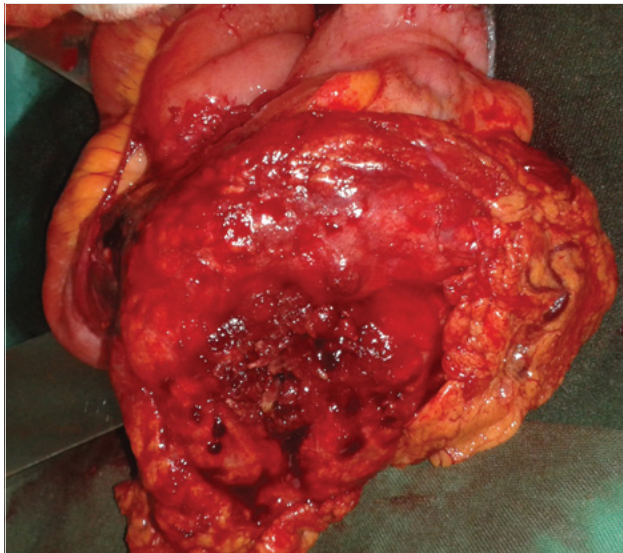


Figure 2. Operative image of inflammatory mass in the cecum and small intestinal segment

emphasized that rather than diagnosis of CD development after appendectomy, CD diagnosis should be made during the surgery period. They evaluated the clinical appendicitis of these cases as the first CD episode (6). CD limited to the appendix is very rare and requires detailed pathological examination (7, 8). In our study, no abnormalities were detected in the appendectomy pathologies, and the first episode of the cases that might be evaluated as CD complication was presented as clinical acute abdomen.

CD is more frequently observed in some locations and regions. In places where it is prevalent, CD should be considered if the provisional diagnosis before the surgery is acute appendicitis and if the patient has atypical, chronic complaints (9, 10). The disease, especially depending on its relationship with the ileum, is characterized by abdominal pain and also diarrhea and anemia. In some cases, low-grade fever, nausea, and vomiting may occur. Fissure in the anal region, fistula, and abscess formations can be observed significantly (11). Furthermore, there may also be an involvement in the extra-intestinal regions, skin and mouth lesions, joint pains, eye symptoms, and kidney and gall bladder stones (12). In our

study, one patient had perianal fistulas and another one had hypoalbuminemia and anemia. Two patients were previously complaining of abdominal pain and diarrhea. One patient suffered from perioral skin lesions.

Despite extensive diagnosis methods such as ultrasonography, CT, X-ray barium, and colonoscopy, the clear diagnosis of CD may still be uncertain (13). The efficacy of the advanced examination methods such as positron emission tomography, enterographic CT, and magnetic resonance imaging are referred in recent studies in the literature (14). In our study, CT was performed in one case because of suspicion of acute abdomen. However, the pathology considered to be the result was interpreted in favor of abscess resulting from acute appendicitis.

In one study, in 12 patients who had undergone surgery for acute appendicitis, CD was detected in the terminal ileum, and although only four patients had appendix inflammation, appendectomy was performed on all patients. Postoperative complications such as abscess or fistula were observed in four patients. It was projected to obtain some preoperative clues through a meticulous examination of the records. It was recommended to consider CD possibility in case of symptoms such as recurrent abdominal pain, diarrhea, and anemia in compliance with chronic process. The differential diagnosis between acute appendicitis and CD is difficult, and a surgical approach for appendicitis is controversial in the presence of CD. In these patients, it is recommended to pay attention primarily to the practical points in preoperative evaluation (15). In another study, on the other hand, in the postoperative follow-up examinations of 14 patients who underwent surgery for acute appendicitis and periappendicular abscess and reported as CD cases after the surgery did not develop enterocutaneous fistula (16). In a patient who had been examined 6 weeks after undergoing appendectomy in another hospital because of discharge from the incision site, enterocutaneous fistula developing as a result of CD was presented in the literature (17). In this study, among the patients who had undergone appendicitis surgery, the patients diagnosed with CD because of complications that developed intraoperatively and postoperatively were examined. Following appendectomy, after developing complications such as enterocutaneous fistula or abscess, diagnosis with CD suspicion is often seen in the literature (17). In our study, enterocutaneous fistula, which developed in two of our patients was observed 3 and 4 weeks, respectively, after appendectomy. While the fistula was closed via conservative treatment in one patient, the other patient was treated with resection of the diseased bowel.

Surgical intervention might be necessary for perforation, perianal fistulas, and obstruction in CD. In case of intra-abdominal abscess development, percutaneous drainage is primarily used in suitable patients, and surgical intervention might be required for others who are not suitable. However, to avoid life-threatening complications, deciding when to apply conservative treatment and when to perform surgical treatment and maintaining a rational approach towards the patient requires maximum attention (3). The patients' course of the disease can be regulated with regular medical treatment. It is a serious but not a fatal disease. In these patients, mortality occurs because of surgical risks and diseases associated with surgery.

Although patients do not have any discomfort, regular follow-up is recommended (2).

During surgery, CDs that were considered as normal appendix and on which appendectomy was performed, development of complications such as enterocutaneous fistula and abscess can be predicted. Therefore, although there is no CD suspicion, it is recommended to perform the surgery as laparoscopic exploration with preliminary diagnosis of acute appendicitis and not performing appendectomy in presence of a normal appendix (6, 15, 18). In our clinic, although we do not have the facility to perform laparoscopic surgery, laparoscopy was performed in most of the appendectomy cases. However, in cases that were presented, the surgeries were performed via laparotomy because appropriate conditions could not be provided. After the evaluation of complicated appendicitis cases, anticipation has developed about pushing the limits.

Conclusion

CD should be remembered in the differential diagnosis of acute abdominal conditions. Although it is difficult to diagnose the disease, nuances should be well studied. In the anamnesis, whether the pain is chronic or not should be questioned, the presence of extra-intestinal symptoms should not be overlooked, and blood tests should be evaluated accurately. It should be kept in mind that a CD during its first episode might emerge as acute clinical abdomen. Following appendectomy surgery in case of unexpected complications such as enterocutaneous fistula, CD should be considered, and further examinations such as ileocolonoscopy should not be delayed during the diagnosis phase.

Ethics Committee Approval: Ethics committee approval was not received due to the retrospective nature of the study.

Informed Consent: Written informed consent was not obtained due to the retrospective nature of the study.

Peer-review: Externally peer-reviewed.

Author Contributions: Concept - O.D., F.B., E.K.; Design - O.D., F.B., E.K.; Supervision - F.B.; Data Collection and/or Processing - O.D., E.K., B.P.; Analyse and/or Interpretation - O.D., F.B., E.K.; Literature Review - O.D., B.P.; Writing - O.D., F.B., E.K., B.P.; Critical Review - F.B., E.K.

Conflict of Interest: No conflict of interest was declared by the authors.

Financial Disclosure: The authors declared that this study has received no financial support.

References

1. Amarapurkar DN, Patel ND, Rane PS. Diagnosis of Crohn's disease in India where Tuberculosis is widely prevalent. *World J Gastroenterol* 2008; 14: 741-6. [\[CrossRef\]](#)
2. Bruce E. Sands, Corey A. Siegel. Crohn's disease. In: Mark Feldman, Lawrence S. Friedman, Lawrence J. Brandt. editors. *Sleisenger & Fordtran's Gastrointestinal and Liver Disease: Pathophysiology, Diagnosis, and Management*. Philadelphia, WB Saunders; 2010. p. 1990-2022.
3. Strong SA, Koltun WA, Hyman NH, Buie WD. Practice parameters for the surgical management of Crohn's disease. *Dis Colon Rectum* 2007; 50: 1735-46. [\[CrossRef\]](#)
4. Hanauer SB, Sandborn W. Management of Crohn's Disease in Adults. *The Am J Gastroenterol* 2001; 96: 635-43. [\[CrossRef\]](#)
5. Sathiyasekaran M, Shivbalan S. Crohn's Disease. *Indian J Pediatr* 2006; 73: 723-9. [\[CrossRef\]](#)
6. Castillo Fernández AL, Paredes Esteban RM, Villar Pastor CM, Ruiz Hierro C, Lasso Betancor CE, Vargas Cruz V, et al. Appendectomy and Crohn's disease. *Cir Pediatr* 2013; 26: 5-8.
7. Alvarez-Blanco M, Fernández-Meré LA, Martínez-Rodríguez E. Crohn's disease of the appendix. *Cir Esp* 2005; 78: 333-5.
8. Prieto-Nieto I, Perez-Robledo JP, Hardisson D, Rodriguez-Monte JA, Larrauri-Martinez J, Gracio-Sancho-Martin L. Crohn's disease limited to appendix. *Am J Surg* 2001; 182: 531-3. [\[CrossRef\]](#)
9. Weston LA, Roberts PL, Schoetz DJ Jr, Collier JA, Murray JJ, Rusin LC. Ileocolic resection for acute presentation of Crohn's disease of the ileum. *Dis Colon Rectum* 1996; 39: 841-6. [\[CrossRef\]](#)
10. Wettergren A, Munkholm P, Grupe Larsent. Granulomas of the appendix: is it Crohn's disease? *Scand J Gastroenterol* 1991; 26: 961-4. [\[CrossRef\]](#)
11. Platell C, Mackay J, Collopy B, Fink R, Ryan P, Woods R. Anal pathology in patients with Crohn's disease. *Aust N Z J Surg* 1996; 66: 5-9. [\[CrossRef\]](#)
12. Thompson NP, Wakefield AJ, Pounder RE. Prognosis and prognostic factors in inflammatory bowel disease. *The Saudi J Gastroenterol* 1995; 1: 129-37.
13. Van Assche G, Dignass A, Panes J, Beaugerie L, Karagiannis J, Allez M, et al. The second European evidence-based Consensus on the diagnosis and management of Crohn's disease: Definitions and diagnosis. *J Crohns Colitis* 2010; 4: 7-27. [\[CrossRef\]](#)
14. Dambha F, Tanner J, Carroll N. Diagnostic imaging in Crohn's disease: what is the new gold standard? *Best Pract Res Clin Gastroenterol* 2014; 28: 421-36. [\[CrossRef\]](#)
15. Oren R, Rachmilewitz D. Preoperative Clues to Crohn's Disease in Suspected, Acute Appendicitis. Report of 12 Cases and Review of the Literature. *J Clin Gastroenterol* 1992; 15: 306-10. [\[CrossRef\]](#)
16. Yang SS, Gibson P, McCaughey RS, Arcari FA, Bernstein J. Primary Crohn's Disease of the Appendix. Report of 14 cases and Review of the Literature *Ann Surg* 1979; 189: 334-9.
17. Machado NO, Chopra PJ, Hamdani AA. Crohn's disease of the appendix with enterocutaneous fistula post-appendectomy: An approach to management. *N Am J Med Sci* 2010; 2: 158-61.
18. Van Dalen R, Bagshaw PF, Dobbs BR, Robertson GM, Lynch AC, Frizelle FA. The utility of laparoscopy in the diagnosis of acute appendicitis in women of reproductive age. *Surg Endosc* 2003; 17: 1311-3. [\[CrossRef\]](#)