

Factors Influencing Diagnostic Success of Computed Tomography-guided Transthoracic Needle Biopsy in Intrathoracic Lesions: An Experience of a Reference Chest Disease Hospital

● Hülya Abalı, ● Nurdan Şimşek Veske, ● Berat Uslu, ● Fatma Tokgöz Akyıl, ● Seda Tural Önür

University of Health Sciences Turkey, Yedikule Chest Diseases and Thoracic Surgery Training and Research Hospital, Clinic of Chest Diseases, İstanbul, Turkey

ABSTRACT

Introduction: Transthoracic needle biopsy (TNB) is a common, safe and inexpensive procedure used in the diagnosis of intrathoracic lesions. Until today, there is still no study about the influence of standardized uptake value (SUV_{max}) in positron emission tomography/computed tomography (PET/CT) on the diagnostic success of TNB in intrathoracic lesions. We aimed to analyze the factors, one of which was the SUV_{max} value influencing the diagnosis success of CT-guided TNB in pulmonary, mediastinal and pleural lesions. Secondary aim was to investigate the predictive clinical factors of complications.

Methods: A retrospective study of 403 patients who underwent CT-guided TNB at a reference chest diseases hospital between February 2019 and February 2021 was conducted. A pulmonologist had performed the procedure with a 20-gauge fine-needle (Spinal) or a 14-gauge automated needle (tru-cut). Data of pathology, microbiology and clinical follow-up of the patients were collected. A chi-square and Student's t-test were used to evaluate the patient-related factors (gender and smoking), lesion-related factors (type, side, location, size, presence of necrosis observed by CT, SUV_{max} value in PET/CT), and procedure factor (type of needle) on the diagnostic success. Additionally, associations between clinical characteristics of patients and the complications were assessed.

Results: A total of 403 patients underwent CT-guided TNB were enrolled and overall success was 70% (284/403). Smoking history (75% vs 43%, $p=0.02$) was predictor for diagnostic success. Lesion size and SUV_{max} value were significantly high in diagnosed patients (for both $p<0.001$). Diagnostic success was high in peripheral and central lesions, more notably in central lesions ($p=0.004$, $p=0.016$, respectively). The 9.2 SUV_{max} cut-off value had sensitivity of 79%, specificity of 53%, success of 79% ($p<0.01$). Cardiovascular diseases, anti-coagulants, vitamin K antagonists, and salicylate induced complications ($p=0.031$, $p=0.022$, $p=0.011$, $p=0.04$, respectively). Low-molecular-weight-heparin was associated with hemorrhage ($p=0.016$).

Conclusion: We observed that type, size and SUV_{max} value of lesion and smoking status were the predictive factors for a diagnostic biopsy.

Keywords: CT-guided, transthoracic biopsy, diagnostic success, SUV_{max} , complications

Introduction

Transthoracic needle biopsy (TNB) is used as an effective and safe diagnostic procedure in the intrathoracic lesions with diagnostic success rates ranging from 12% to 68% in benign (1), and from 76% to 97% in malignant lesions (2,3).

Computed tomography (CT) is an auxiliary radiological device with a perfect visualization capability used for TNB of the intrathoracic lesions. Real-time guidance of CT is a non-invasive marking and confirming method that allows high diagnostic success rates (4).

The most common complications of the procedure are pneumothorax (4-54%), followed by parenchymal hemorrhage at a rate of 2-42% (5,6). Chronic diseases and long-term medications of the patients have influence on the complications. Perilesional emphysema induces pneumothorax and hemorrhage (7). Antiplatelet and anti-coagulative long-term medications are risk factors for hemoptysis (8).

The main aim of this study was to contribute to the literature with the outcomes of the reference chest diseases hospital's experience in the factors influencing the diagnostic success rate of CT-guided TNB in intrathoracic lesions consisting of pulmonary, pleural, and mediastinal.



The present study was presented verbally at the Hybrid Turkish Thorax Congress in Antalya on 19.11.2021.

Address for Correspondence: Hülya Abalı MD, University of Health Sciences Turkey, Yedikule Chest Diseases and Thoracic Surgery Training and Research Hospital, Clinic of Chest Diseases, İstanbul, Turkey
Phone: +90 505 758 42 97 **E-mail:** hulayab@gmail.com **ORCID ID:** orcid.org/0000-0003-4041-7479

Cite this article as: Abalı H, Şimşek Veske N, Uslu B, Tokgöz Akyıl F, Tural Önür S. Factors Influencing Diagnostic Success of Computed Tomography-guided Transthoracic Needle Biopsy in Intrathoracic Lesions: An Experience of a Reference Chest Disease Hospital. *İstanbul Med J* 2023; 24(1): 14-21.

Received: 23.05.2022

Accepted: 20.12.2022

Among these factors, the influence of maximum standardized uptake (SUV_{max}) value in positron emission tomography/computerized tomography (PET/CT) on diagnostic success was also analyzed. Additionally, the predictive clinical factors for complications were investigated.

Methods

This single-center study was approved by the Local Ethics Committee of University of Health Sciences Turkey, Yedikule Chest Diseases and Thoracic Surgery Training and Research Hospital (approval number: 2021-107, date: 08.04.2021). Four hundred-three patients who underwent CT-guided TNB performed by five independent pulmonologists between February 2019 and February 2020 were analyzed retrospectively. Because of the retrospective design of the study, the patients were exempt from informed consent.

Data Collection and Measurements

Data of the study were obtained from the hospital registration system. Demographic characteristics of the patients (gender and smoking status) and the type of needle used were collected.

Lesion type was categorized as a solitary pulmonary nodule, multiple pulmonary nodules, central mass, peripheral mass, mediastinal mass, pleural mass, consolidation, abscess, and cavitary lesion in thoracic CT. The central mass was described as a mass in the 2/3 inner area of the pulmonary parenchyma, and peripheral mass was described as a mass in the 1/3 outer area of the pulmonary parenchyma.

Smoking status was grouped as ever-smoker and never-smoker. Ever-smokers included former and current smokers.

Size (cm), side (right/left/bilateral lung), location (right upper/middle/right lower lobe; left upper/lingula/left lower lobe), and necrosis content of a lesion in thoracic CT were recorded. The size of a lesion (cm) was classified as <1, 1-3, 3-5, >5.

The SUV is an activity concentration in the tissue, which is calculated by radionuclide dose administered/patient's weight. SUV_{max} values of the patients whose PET/CT reports could be accessed in the hospital registry system, were collected.

Procedural complications (pneumothorax, hemorrhage, air embolism, syncope) were collected from the interventional radiology registration system. Chronic diseases [chronic pulmonary diseases (CPD) (chronic obstructive pulmonary disease (COPD), emphysema, asthma), chronic cardiovascular diseases (CVD) (coronary artery disease, heart failure, hypertension)], and long-term medications such as anti-coagulant drugs [new oral anti-coagulants (NOAC), parenteral direct and indirect anti-coagulants], vitamin K antagonists, low-molecular-weight-heparin (LMWH), and antiplatelet drugs (salicylate and clopidogrel) were recorded from the pharmacy Medulla system.

Transthoracic Needle Biopsy Procedure

By the routine practice of the hospital and the Helsinki Declaration, consent was obtained from the patients for the procedure. All procedures were performed by five independent researcher pulmonologists with at least 10 years of professional experience.

A 16-slice CT scanner (Toshiba Alexion model 2013, Nasu, Japan) was used to guide the needle and locate the lesion. Anti-coagulant drugs were discontinued at least one week before the procedure. PET/CT and thoracic CT were pre-examined for biopsy site determination. A patient was positioned on the CT table according to the safest and shortest crossing for the biopsy and told to hold a breath. The location of a lesion was confirmed by a CT scanner. The needle -entry site of the skin was marked by an accompanying technician. After local antiseptics, the needle was inserted through the lesion. A 9 cm-long, 20-gauge fine needle (Spinal) was used for aspiration biopsy, and a 20 cm-long, 14-gauge automated needle (tru-cut) was used for core biopsy. The aspiration was performed once it was ascertained that the needle was exactly inside the lesion.

After aspiration of the adequate sample, the aspirated material was fixed in 96% alcohol solution. A core specimen was fixed in 10% formalin. Frozen section analysis was not performed at the time of the biopsy. The collected material was sent to the department of pathology for histopathological examination. The samples of patients with suspected pulmonary tuberculosis were sent to the department of microbiology for acid fast bacilli (AFB) staining and culture to identify mycobacterial infection.

End-point of the Study

The pathological results were classified into three categories-malignant, benign, and non-diagnostic. The result of pathology as malignant or benign was deemed as a diagnostic success. AFB staining positivity and/or mycobacterium species proliferation in culture were also deemed as diagnostic success.

Statistical Analysis

All statistical analyses were carried out using a statistical software package (SPSS for Windows, version 16.0; SPSS Inc.; Chicago, IL, USA). Quantitative data were expressed as mean \pm standard deviation and qualitative data were expressed as frequencies. A chi-square and Student's t-test were used to evaluate the data obtained from inter-group comparison. Receiver operating characteristic (ROC) analysis was used to determine the optimal SUV_{max} cut-off value in PET/CT. A p-value of <0.05 was considered significant.

Results

Four hundred-three patients underwent CT-guided TNB mainly with a prediagnosis of malignant diseases. The mean age of the patients, 81% (327) of whom were male, was 63 ± 12 years. Eighty-nine percent of the patients (n=358) had a smoking history (Table 1).

The diagnostic success rate of TNB was 70% (284 of 403 patients). Two hundred-sixty-nine (95%) out of 284 patients were diagnosed with malignant disease, and 15 (5%) out of 284 patients were diagnosed with benign diseases by TNB. Of the benign lesions, only one was diagnosed with pulmonary tuberculosis based on microbiological examination [sample ARB (+)]. While the histopathological type was non-small-cell lung cancer in 220 patients and small cell lung cancer in 25 patients (Table 2).

Table 1. Demographic, clinical, and radiological characteristics of patients underwent transthoracic needle biopsy for intrathoracic lesion

	Number (n)	Percentages (%)
Gender		
Male	327	81
Female	76	19
Smoking status		
Ever-smoker	358	89
Never-smoker	45	11
Chronic diseases		
Cardiovascular diseases	117	29
Pulmonary diseases	98	24
Anti-coagulant drugs (one or more)		
Vitamin K antagonists	17	4
Low-molecular-weight-heparin	14	4
Anti-platelet drugs		
Clopidogrel	14	4
Salicylate	73	18
Lesion type		
Solitary pulmonary nodule	58	14
Multiple pulmonary nodules	16	4
Peripheral mass	236	59
Central mass	39	10
Mediastinal mass	7	1
Pleural mass	14	4
Consolidation	11	3
Cavitary lesion	15	4
Abscess	2	1
Lesion size (cm)		
<1	4	1
1-3	93	23
3-5	114	28
>5	192	48
Necrosis		
Yes	105	26
No	298	74
Lesion side (lung)		
Right	205	51
Left	196	48.6
Bilateral	2	0.4
Lesion location (lobe)		
Right upper	117	29
Middle	20	5
Right lower	73	18
Left upper	97	24
Lingula	11	3
Left lower	85	21

Among 119 patients undiagnosed by TNB, 18 patients were diagnosed via either bronchoscopy, endobronchial ultrasonography, video-assisted thoracoscopy, or open lung biopsy, and 4 patients were diagnosed clinically and radiologically by a pulmonologist (Table 2). No repeated TNB was applied. Out of 119 undiagnosed by TNB, 97 patients dropped out of our follow-up for unknown reasons.

The most common lesion type was the peripheral lesion (n=236, 59%), and the most common lesion location was the right upper lobe

Table 2. Diagnosis of patients

	Number (n)	Percentages (%)
Diagnosis by TNB		
Malign	269	95
SCLC	25	8.8
NSCLC	220	77.4
NSCLC with an undefined subtype	47	16.5
SqCLC	81	28.5
Adenocarcinoma	92	32.4
Mesothelioma	2	0.7
Mesenchymal tm	6	2.1
Neuroendocrine tm	3	1.1
Extrapulmonary cancer metastasis	13	4.6
Benign	15	5
Anthracosis	1	0.4
Sarcoidosis	3	1.1
Pulmonary tuberculosis	6	0.4
Organizing pneumonia	3	1.1
Aspergillus infection	1	0.4
Fungal infection	1	0.4
Diagnosis by a pulmonologist		
Infected bronchiectasis	1	25
Metastatic lung cancer	2	50
Primary lung cancer	1	25
Diagnosis by further invasive procedures		
Malignant solitary fibrous tm	1	5.6
Wilms tm	1	5.6
Anthracosis	1	5.6
B-cell Lymphoma	3	16.2
Hamartoma	1	5.6
Hyalinization	1	5.6
Mesothelioma	1	5.6
SCLC	1	5.6
Invasive mucinous carcinoma	1	5.6
SqCLC	2	11.1
Adenocarcinoma	1	5.6
Sarcomatous tm	1	5.6
Pulmonary tuberculosis	2	11.1
Lung metastasis from thyroid cancer	1	5.6

NSCLC: Non-small-cell lung cancer, SCLC: Small-cell lung cancer, SqCLC: Squamous-cell lung cancer, tm: Tumor, TNB: Transthoracic needle biopsy

Table 3. Associations between lesion type, location, and SUV_{max} value in PET/CT and diagnostic success of transthoracic needle biopsy in intrathoracic lesions

	Success	Failure	p
	n=284 (70%)	n=119 (30%)	
Lesion type			
Peripheral mass	184 (76)	58 (24)	-
Solitary pulmonary nodule	38 (65)	20 (35)	-
Multiple pulmonary nodules	11 (69)	5 (31)	-
Central mass	34 (87)	5 (13)	<0.001*
Mediastinal mass	1 (14)	6 (86)	-
Pleural mass	7 (50)	7 (50)	-
Consolidation	4 (36)	7 (64)	-
Cavitary lesion	5 (33)	10 (67)	-
Abscess	0 (0)	2 (100)	-
SUV _{max} value in PET/CT (μCu/g)	[#] 15±7.5	[#] 11±7.7	<0.001*
Lesion side (lung)			
Right	142 (69)	63 (31)	-
Left	141 (72)	55 (28)	0.688*
Bilateral	1 (50)	1 (50)	-
Lesion location (lobe)			
Right upper	88 (65)	29 (35)	0.145
Right middle	14 (70)	6 (30)	0.998
Right lower	44 (62)	27 (38)	0.087
Left upper	71 (74)	26 (26)	0.437
Lingula	8 (73)	3 (27)	0.998
Left lower	62 (73)	23 (27)	0.410

Percentage values given in parentheses, [#]mean value ± standard deviation, n: Number of patients, PET/CT: Positron emission tomography/computed tomography, SUV_{max}: Maximum value of standardized uptake, *p<0.05: Significant value

(n=210, 52%) (Table 1). While the diagnostic success rate of TNB was 76% in patients with peripheral lesions (p=0.004), it was 87% in central lesions (p=0.016). The diagnostic success rate was significantly lower in a mediastinal lesion (14% vs 86%, p=0.003). Five of 15 patients with cavitary lesions were diagnosed (33% vs 67%, p=0.003). Four of 11 patients with consolidations had definite diagnoses (36% vs 64%, p=0.018) (Table 3).

An ever-smoker patient had higher diagnostic success than a never-smoker patient (75% vs 43%, p=0.02) as shown in Table 4.

The mean lesion size of all patients was 5.5±2.9 cm. While the mean size of central lesions was 5.5±2.9 cm, the mean size of peripheral lesions was 5.9±2.2 cm. The procedural diagnostic rates of patients with the lesion size (cm) <1, 1-3, 3-5, >5 were 50%, 60%, 72%, and 79%, respectively. The mean SUV_{max} value of the lesions was 13.8±7.8 μCu/g. The lesion size and SUV_{max} value were statistically significantly higher in patients with a pathology diagnosis (for both, p<0.001) (Table 4).

The optimal SUV_{max} cut-off value for the diagnostic success of TNB was detected as 9.2 μCu/g (area under the curve: 0.669) by ROC analysis. TNB procedure was 21% diagnostic in patients with an SUV_{max} value below 9.2 μCu/g, and 79% in those with an SUV_{max} value above 9.2 μCu/g (p<0.001). The SUV_{max} value above 9.2 μCu/g had a sensitivity of 79% and specificity of 53% for the diagnostic success of CT-guided TNB (Figure 1).

The complications were observed in 9% (n=35) patients. The most common complication was pneumothorax at a percentage of 7% (n=29) patients, followed by hemorrhage in 2% (6) patients. None of the air embolism and syncope appeared among the complications.

CPD were recorded in 98 (24%) patients, and CVD were recorded in 117 (29%) patients (Table 1). Clinical characteristics such as anti-coagulant and antiplatelet drug use and chronic diseases of patients were compared with complications and hemorrhage rates. Statistically significant correlations were found between the development of complications and the history of CVD (p=0.031), the administration of anti-coagulant drugs (NOAC, parenteral direct and indirect anti-coagulants) (p=0.022), vitamin K antagonists (p=0.011), and salicylate (p=0.04). LMWH administration had a significant influence on hemorrhage (p=0.016). No significant associations were found between smoking and CPD and the occurrence of pneumothorax (p=0.998, p=0.415) (Table 5).

Discussion

The fast diagnosis of an intrathoracic lesion suspected for malignancy is important to avoiding mortality and morbidity of cancer by administering the optimal treatment as soon as possible.

TNB achieves a high technical success rate of 88-97% in different studies (9-11). The diagnostic success rate of this study was 70% (284 of 403 patients) compatible with the reported ranges.

Table 4. Influence of demographic and lesion characteristics of the patients and needle type on the diagnostic success of transthoracic needle biopsy in intrathoracic lesions

	Success	Failure	p
	n=284 (70%)	n=119 (30%)	
Gender			
Male	236 (72)	91 (28)	0.127
Female	48 (63)	28 (37)	-
Smoking history			
Ever-smoker	268 (75)	90 (25)	<0.001*
Never-smoker	19 (42)	26 (58)	-
Lesion size (cm)			
	^β 2.3±0.8	^β 2±0.9	<0.001*
<1 cm	2 (50)	2 (50)	-
1-3	52 (60)	41 (40)	<0.001*
3-5	82 (72)	32 (38)	-
>5	151 (79)	41 (31)	-
Necrosis in lesion			
Yes	72 (69)	33 (31)	0.621
No	212 (71)	86 (29)	-
Needle type			
FNB	268 (70)	115 (30)	0.454
CB	16 (80)	4 (20)	-

Percentage values given in parentheses, ^βmean value ± standard deviation, CB: Core biopsy, FNB: Fine-needle biopsy, n: Number of patients, *p<0.05: Significant value

Table 5. Associations between clinical characteristics of patients and complications of transthoracic needle biopsy in intrathoracic lesions

		Number (n)	Percentages (%)	p
Total complications	Anti-coagulants (n=95)	14	15	0.022*
	Vitamin K antagonists (n=17)	5	29	0.011*
	LMWH (n=14)	2	14	0.347
	Salicylate (n=73)	11	15	0.040*
	Clopidogrel (n=14)	1	7	1.000
	CPD (n=98)	6	6	0.410
	CVD (n=117)	16	14	0.031*
Pneumothorax	Ever-smoker (n=358)	18	5	0.998
	CPD (n=98)	29	29	0.415
Hemorrhage	Anti-coagulants (n=95)	3	3.2	0.146
	Vitamin K antagonists (n=17)	0	0	0.998
	LMWH (n=14)	2	14.3	0.016*
	Salicylate (n=73)	3	4.1	0.076
	Clopidogrel (n=14)	0	0	0.999

CPD: Chronic pulmonary diseases, CVD: Cardiovascular diseases, LMWH: Low-molecular-weight-heparin. *p<0.05: Significant value

The diagnostic success of TNB performed by a pulmonologist in a study including 224 patients was reported at 97% (12). The relatively low diagnostic success in this study may be explained by the lesions containing more necrotic tissues. Another fact is that diagnostic success seems to be higher in the case of TNB performed in the presence of a pathologist to evaluate sample adequacy (13). Unfortunately, no accompanying pathologist was present during the procedure in the interventional radiology department.

The procedure in 185 of 247 ever-smoker patients were diagnostic, and there was a significant association between smoking history and diagnostic success (p<0.001). This result was not surprising in this study with the malignant pathology results at a rate of 95%.

van Sonnenberg et al. (14) have determined the diagnostic success of 90% for lesions 3-4 cm, 89.3% for lesions 2-3 cm, 83.9% for lesions 1-2 cm, and 73.9% for lesions <1 cm (14). Tsukada et al. (15) have reported that diagnostic success decreased with decreasing lesion size (cm):

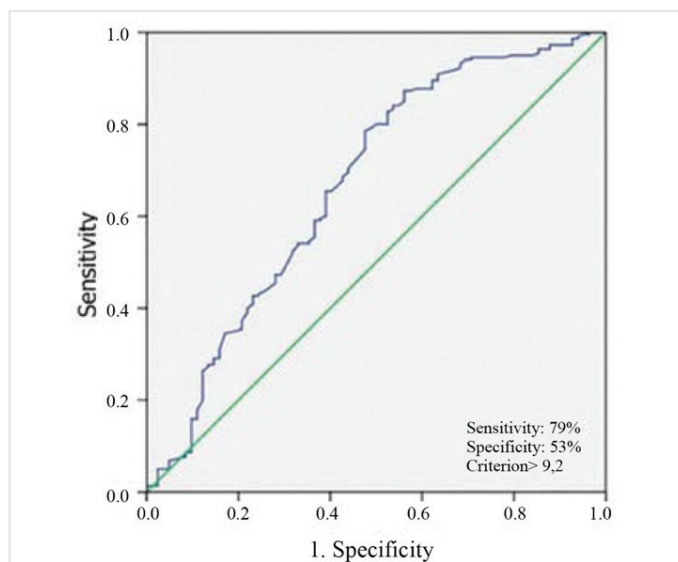


Figure 1. The ROC curves of the sensitivity and specificity of SUV_{max} above 9.2 $\mu Cu/g$ of cut-off value

ROC: Receiver operating characteristic

from 100% to 93%, 87%, 79%, and 67% for lesions >5, 3-5, 2-3, 1-2, <1, respectively. The diagnostic success related to the lesion size (cm) agreed with the previous studies: for <1, 1-3, 3-5, and >5 were 50%, 60%, 72%, and 79%, respectively. Lesions at a mean size of 2.3 ± 0.8 cm had significant diagnostic success of TNB ($p < 0.001$). Li et al. (9) have attributed the decrease in diagnostic success with the reduction in lesion size to sampling error. Because the technique of targeting small lesions is difficult, the needle can not be placed right inside the lesion or it can be placed in a necrosed area. Controversially, Priola et al. (13) have showed that diagnostic success was high in the lesions of which sizes were 1.5-5 cm (lesions <1.5 cm 68%, lesions 1.5-5.0 cm 87%, lesions >5 cm 78%). Another study has declared that CT-guided TNB of small pulmonary lesions <2 cm had higher diagnostic success (93.5%) (16). Luciderma et al. (17) have reported no significant difference in the success of 81% for ≤ 2 cm and 91% for lesions >2 cm. These conflicts may depend on the needle type and skill of the practitioner.

Peripheral and central lesions had significant influences on diagnostic success ($p = 0.004$, $p = 0.016$, respectively; conversely, mediastinal mass, cavitory lesion, and consolidation had significant influences on diagnostic failure ($p = 0.003$, $p = 0.003$, $p = 0.018$, respectively) in this study. To date, there are few studies analyzing the influence of lesion type on the diagnostic value of this procedure. The diagnostic success rate of CT-guided TNB with a fine needle was 83.5% in central lesions, and diagnostic success increased gradually to the periphery of the lung to 95.6% in the study by De Filippo et al. (18). The lesion depth had no significant influence on the diagnostic success in another study (19). Unlikely these two studies, the diagnostic success rate of TNB was higher in central lesions in this study. Different outcomes of the three studies may be related to the differences in the mean lesion size and needle-pleural angle.

In some series of studies, the diagnostic success rates of TNB in cavitory lesions have been found at 100% and 94% (18,19). However,

the diagnostic success rate was observed as 33% in this study. A study including 1,090 patients have declared that the diagnostic rate of TNB in consolidations is at 83% (20). On the contrast, the diagnostic success of TNB in consolidations was found to be 36%. The lower rates of diagnostic success in cavitory lesions and consolidations may be attributed to the lower percentages of these radiological appearances in this study.

The mean SUV_{max} value of the lesions was 13.8 ± 7.8 $\mu Cu/g$ and was significantly high in diagnosed patients. In the current literature, there is no study on the cutoff value of SUV_{max} , which indicates the diagnostic success of TNB in intrathoracic lesions. A previous study (21) including the nodules in the size of 1-2 cm has investigated the SUV_{max} cut-off value for the diagnostic success of TNB. The 4.5 SUV_{max} cut-off value had a sensitivity of 80.2%, specificity of 54.4%, accuracy of 72.8% ($p < 0.001$). Similarly, the 9.2 SUV_{max} cut-off value had sensitivity of 79%, specificity of 53%, and accuracy of 79% ($p < 0.001$) in this study. The SUV_{max} value above 2.5 $\mu Cu/g$ predicted malignant lesions (22). While 58% of the lesions were malign in the previous study, 95% of the lesions were malign in this study. Compared with that study, the higher SUV_{max} cut-off value in this study had approximately the same specificity. This might be because our study included a higher proportion of malignant and infected lesions as F-18 fluorodeoxyglucose is not uptaken only by malign lesions but also by inflammatory lesions (23).

The most common complication was pneumothorax, followed by hemorrhage. The rates of these complications were within acceptable levels and even were less than that reported in the previous literature (5,6,24). Emphysema and smoking have been declared as risk factors for pneumothorax and hemorrhage in a study (25). Controversially, CPD and smoking had no influence on the occurrence of pneumothorax in this study. Another study has also found no association between smoking and pneumothorax (26). In a study, COPD has been reported as a risk factor for both pneumothorax and hemorrhage, and oral anti-coagulants and antiplatelet agents have been reported as risk factors for hemorrhage (27). Conversely, CPD had no association with total complications, and anti-coagulants and antiplatelet agents (salicylate, clopidogrel) had no associations with hemorrhage. LMWH was found to be the only risk factor for hemorrhage. However, anti-coagulants, salicylate, and vitamin K antagonists had associations with total complications (pneumothorax and hemorrhage). A previous study reported that hypertension was not a risk factor for complications of TNB, including pneumothorax, hemorrhage, hemoptysis, and hemothorax (28). In contrast, CVD was a significant factor in the occurrence of total complications in this study. Lesions of different sizes and depths, different patient populations may have led to the conflict between these studies.

Study Limitations

The main limitation of this study was the retrospective design. We consider that the most important reason for undiagnosed 97 patients to drop out of our follow-up is the coincident of the diagnostic interventions with the COVID-19 pandemic period.

Conclusion

This study demonstrated that lesion-related factors (type, size, SUV_{max} value in PET/CT) and patient-related factors (smoking history) were

predictors for the diagnostic success of TNB. The history of CVD, administration of anti-coagulants, vitamin K antagonists, and salicylate were observed to correlate with the higher complication rates. An association was observed between hemorrhage and only LMWH. Before ordering this procedure, a practitioner should consider these factors.

Acknowledgments

All authors thank the staff of the radiology department and Dilara Demir for her contribution in designing tables and figures.

Ethics Committee Approval: This single-center study was approved by the Local Ethics Committee of University of Health Sciences Turkey, Yedikule Chest Diseases and Thoracic Surgery Training and Research Hospital (approval number: 2021-107, date: 08.04.2021).

Informed consent: The patients were exempt from informed consent.

Peer-review: Externally peer-reviewed.

Authorship Contributions: Surgical and Medical Practices - H.A., N.Ş.V., B.U., F.T.A., S.T.Ö.; Concept - H.A.; Design - H.A., N.Ş.V., B.U.; Data Collection or Processing - H.A., N.Ş.V., B.U., F.T.A., S.T.Ö.; Analysis or Interpretation - H.A., N.Ş.V., B.U., F.T.A., S.T.Ö.; Literature Search - H.A.; Writing - H.A., F.T.A., S.T.Ö.

Conflict of Interest: No conflicts of interest were declared by the authors.

Financial Disclosure: The authors received no financial support for the research and/or authorship of this article.

References

- Perlmutter LM, Johnston WW, Dunnick NR. Percutaneous transthoracic needle aspiration: a review. *AJR Am J Roentgenol* 1989; 152: 451-5.
- Anderson JM, Murchison J, Patel D. CT-guided lung biopsy: factors influencing diagnostic yield and complication rate. *Clin Radiol* 2003; 58: 791-7.
- Larscheid RC, Thorpe PE, Scott WJ. Percutaneous transthoracic needle aspiration biopsy: a comprehensive review of its current role in the diagnosis and treatment of lung tumors. *Chest* 1998; 114: 704-9.
- Klein JS, Zarka MA. Transthoracic needle biopsy. *Radiol Clin North Am* 2000; 38: 235-6.
- Klein JS, Salomon G, Stewart EA. Transthoracic needle biopsy with a coaxially placed 20-gauge automated cutting needle: results in 122 patients. *Radiology* 1996; 198: 715-20.
- Lasparis F, Roussakis A, Efthimiadou R, Papaioannou D, Papadopoulos S, Andreou J. Percutaneous CT-guided fine-needle aspiration of pulmonary lesions: results and complications in 409 patients. *J Med Imaging Radiat Oncol* 2008; 52: 458-62.
- Lee DS, Bak SH, Jeon YH, Kwon SO, Kim WJ. Perilesional emphysema as a predictor of risk of complications from computed tomography-guided transthoracic lung biopsy. *Jpn J Radiol* 2019; 37: 808-16.
- Hwang EJ, Park CM, Yoon SH, Lim HJ, Goo JM. Risk factors for haemoptysis after percutaneous transthoracic needle biopsies in 4,172 cases: Focusing on the effects of enlarged main pulmonary artery diameter. *Eur Radiol* 2018; 28: 1410-9.
- Li H, Boiselle PM, Shepard JAO, Trotman-Dickenson B, McCloud TC. Diagnostic accuracy and safety of CT-guided percutaneous needle aspiration biopsy of the lung: comparison of small and large pulmonary nodules. *AJR Am J Roentgenol* 1996; 167: 105-10.
- Chojniak R, Isbemer RK, Viana LM, Yu LS, Aita AA, Soares FA. Computed tomography guided needle biopsy: experience from 1,300 procedures. *Sao Paulo Med J* 2006; 124: 10-4.
- Guimarães MD, Marchiori E, Hochegger B, Chojniak R, Gross JL. CT-guided biopsy of lung lesions: defining the best needle option for a specific diagnosis. *Clinics (Sao Paulo)* 2014; 69: 335-40.
- Ahn JH, Jang JG. Initial Experience in CT-Guided Percutaneous Transthoracic Needle Biopsy of Lung Lesions Performed by a Pulmonologist. *J Clin Med* 2019; 8: 821.
- Priola AM, Priola SM, Cataldi A, Errico L, Di Franco M, Campisi P, et al. Accuracy of CT-guided transthoracic needle biopsy of lung lesions: factors affecting diagnostic yield. *Radiol Med* 2007; 112: 1142-59.
- van Sonnenberg E, Casola G, Ho M, Neff CC, Varney RR, Wittich GR, et al. Difficult thoracic lesions: CT-guided biopsy experience in 150 cases. *Radiology* 1988; 167: 457-61.
- Tsukada H, Satou T, Iwashima A, Souma T. Diagnostic accuracy of CT-guided automated needle biopsy of lung nodules. *AJR Am J Roentgenol* 2000; 175: 239-43.
- Li Y, Du Y, Yang HF, Yu JH, Xu XX. CT-guided percutaneous core needle biopsy for small (≤ 20 mm) pulmonary lesions. *Clin Radiol* 2013; 68: e43-8.
- Luciderma O, Howarth N, Finet JF, Grenier PA. Intrapulmonary lesions: percutaneous automated biopsy with a detachable, 18-gauge, coaxial cutting needle. *Radiology* 1998; 207: 759-65.
- De Filippo M, Saba L, Concari G, Nizzoli R, Ferrari L, Tiseo M, et al. Predictive factors of diagnostic accuracy of CT-guided transthoracic fine-needle aspiration for solid noncalcified, subsolid and mixed pulmonary nodules. *Radiol Med* 2013; 118: 1071-81.
- Arslan S, Yilmaz A, Bayramgürler B, Uzman O, Nver E, Akkaya E. CT-guided transthoracic fine needle aspiration of pulmonary lesions: Accuracy and complications in 294 patients. *Med Sci Monit* 2002; 8: 493-7.
- Kiranantawat N, Petranović M, McDermott S, Gilman M, Digumarthy SR, Shepard JO, et al. Feasibility and accuracy of CT-guided percutaneous needle biopsy of cavitary pulmonary lesions. *Diagn Interv Radiol* 2019; 25: 435-41.
- Yeow KM, Tsay PK, Cheung YC, Lui KW, Pan KT, Chou AS. Factors affecting diagnostic accuracy of CT-guided coaxial cutting needle lung biopsy: retrospective analysis of 631 procedures. *J Vasc Interv Radiol* 2003; 14: 581-8.
- Kiranantawat N, McDermott S, Fintelmann FJ, Montesi SB, Price MC, Digumarthy SR, et al. Clinical role, safety and diagnostic accuracy of percutaneous transthoracic needle biopsy in the evaluation of pulmonary consolidation. *Respir Res* 2019; 20: 23.
- Susam S, Çinkooğlu A, Ceylan KC, Gürsoy S, Kömürçüoğlu BE, Mertoğlu A, et al. Diagnostic success of Transthoracic needle biopsy and PET-CT for 1 to 2 cm solid indeterminate pulmonary nodules. *Clin Respir J* 2020; 14: 453-61.
- Menda Y, Bushnell DL, Madsen MT, McLaughlin K, Kahn D, Kernstine KH. Evaluation of various corrections to the standardized uptake value (SUV) for diagnosis of pulmonary nodules. *Nucl Med Commun* 2001; 22: 1077-81.
- Gould MK, Maclean CC, Kuschner WG, Rydzak CE, Owens DK. Accuracy of positron emission tomography for diagnosis of pulmonary nodules and mass lesions: a meta-analysis. *JAMA* 2001; 285: 914-24.
- Boskovic T, Stanic J, Pena-Karan S, Zarogoulidis P, Drevelegas K, Katsikogiannis N, et al. Pneumothorax after transthoracic needle biopsy of lung lesions under CT guidance. *J Thorac Dis* 2014; 6(1 Suppl): S99-S107.
- César DN, Torres US, D'Ippolito G, Souza AS. CT-guided Transthoracic Core-Needle Biopsies of Mediastinal and Lung Lesions in 235 Consecutive Patients: Factors Affecting the Risks of Complications and Occurrence of a Final Diagnosis of Malignancy. *Arch Bronconeumol* 2018; 55: 297-305.

28. Taslakian B, Koneru V, Babb JS, Sridhar D. Transthoracic Needle Biopsy of Pulmonary Nodules: Meteorological Conditions and the Risk of Pneumothorax and Chest Tube Placement. *J Clin Med* 2019; 8: 727.
29. Vachani A, Zhou M, Ghosh S, Zhang S, Szapary P, Gaurav D, et al. Complications After Transthoracic Needle Biopsy of Pulmonary Nodules: A Population-Level Retrospective Cohort Analysis. *J Am Coll Radiol* 2022; 19: 1121-9.
30. Digumarthy SR, Kovacina B, Otrakji A, Lanuti M, Shepard JA, Sharma A. Percutaneous CT guided lung biopsy in patients with pulmonary hypertension: Assessment of complications. *Eur J Radiol* 2016; 85: 466-71.